

Regional Anesthesia for Shoulder Girdle Surgery

Robert M Raw MD

MBChB, MPrax Med, MFGP, DA FCA

Professor of Anesthesia retired.

Editor Regional-Anesthesia.Com

rob-raw@outlook.com

Version 2018-April, revised 2019-April.

INTRODUCTION

The majority of surgery for this region is orthopedic and shoulder girdle surgery is very common. The region is very amenable to peripheral nerve blocks. Typically the blocks are combined with general anesthesia for patient comfort reasons due to the unusual positions needed for the surgery or the amount of traction and movements the patient is subjected to. Traction and manipulation on the shoulder girdle is felt by the patient at the attachment of the girdle to the thorax and neck outside of the zone of anesthetized tissues.

The interscalene block is very popularly and successfully used for shoulder joint (gleno-humeral joint) surgery. However it is less common knowledge what are the necessary nerve blocks are for surgery of the scapula, clavicle and axial muscles attached to the shoulder girdle. This lecture will elaborate on that.

The benefits of nerve blocks provide are;

- Ability to use a lighter general anesthetic which in turn has (i) less myocardial and vascular system depressive effects, (ii) faster patient recovery to alertness,
- Reduction in post surgical opiate use resulting in (i) less nausea, (ii) less pruritus, (iii) respiratory depression, and (iv) constipation.
- Provide profound analgesia. This is the prime benefit. It is humanitarian and caring to treat pain.

A big challenge of regional anesthesia for the shoulder girdle is that the shoulder girdle inherently (1) has high incidence of underlying incidental nerve injury, and (2) the surgery carries inherent risks for nerve injury via many mechanisms in particular from stretching of the nerve. Nerve blocks have their own risks for causing nerve injury and attributing the correct mechanism to an injury is often impossible.

WHAT IS THE SHOULDER GIRDLE?

The main part of the shoulder girdle is the clavicle, scapular and glenohumeral joint. The only joint attachment of the shoulder girdle to the body trunk is via the sternoclavicular joint. The rest of the shoulder girdle is attached via muscles to the axis and the shoulder girdle pivots on the sternoclavicular joint.

The shoulder girdle consists of (1) bones, (2) muscles, (3) skin, and (4) joints, and the adjacent chest cage can be involved in surgery too. These elements despite being adjacent to each other or joining each other may each have root origins of their own different nerve supplies. This may make regional anesthesia complex.

The three shoulder girdle bones are the (i) *scapular* to posterior, the (ii) *proximal humerus* to lateral and the (iii) *clavicle* to anterior. The joints are (i) the *glenohumeral joint* [shoulder joint], (ii) the *sternoclavicular joint*, and (iii) the *acromioclavicular joint*.

All of these elements primarily have nerve supplies from C5-6-7 from where the primitive upper limb bud formed. The uppermost pre-axial muscles have a nerve supply from C5-6-7s, and the post part of arm and hands have some C8 and T1 supply as well.

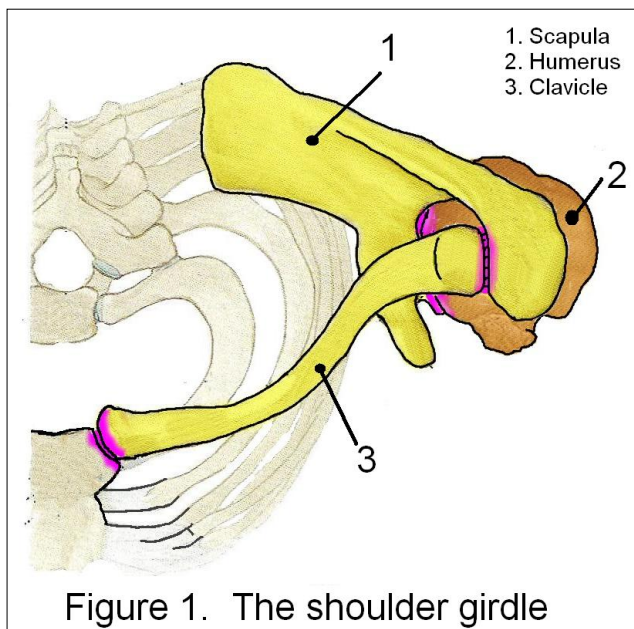


Figure 1. The shoulder girdle

Advertising space. Attention, academic supporters, sponsors and advertisers. This banner space on page #1 of this document, is available for advertising on the web available free copies of this lecture, at Regional-Anesthesia.Com. You can also place a dynamic link on the banner, to your website. If interested contact editor@regional-anesthesia.com.

EVOLUTION AND EMBRYOLOGY OF THE SHOULDER GIRDLE

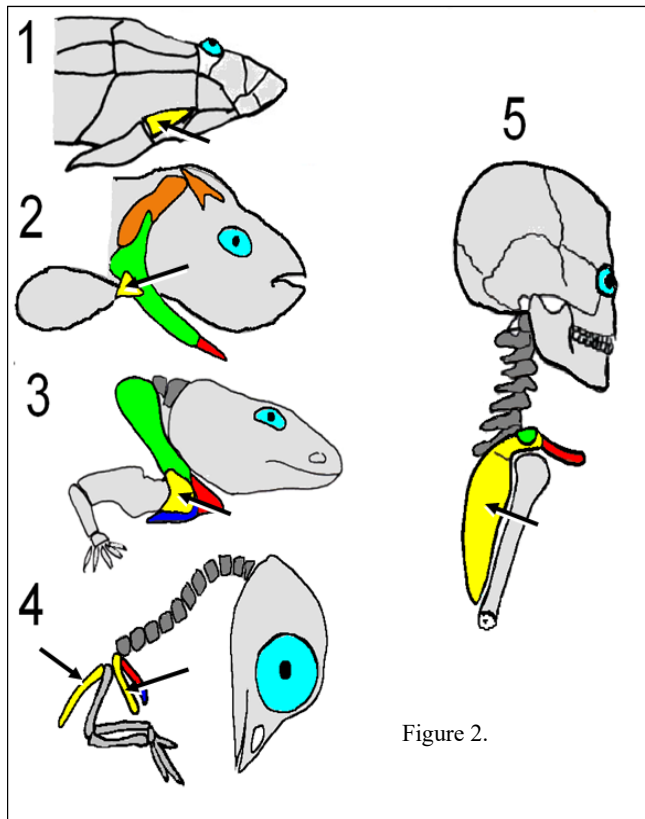


Figure 2.

The term *evolution* describes the serial differences observed on in the structure of the shoulder girdle from primitive extinct fish to complex modern humans. “Intermediate development” is seen in living reptiles and other mammals. Knowing the evolution helps understand the nerve supply of different shoulder girdle components.

The earliest pectoral girdle acted as a connection between the fin and the head and was embryologically part of the head (Figure 2, number 1). More components developed in the pectoral girdle as the complexity of the fin’s articulation with the pectoral girdle increased (figure 2, number 2). With land living amphibians the first cervical vertebra developed separating the forelimb (pectoral) girdle from the head (figure 2, number 3). With creatures developing after amphibians as in birds and mammals extra cervical vertebrae developed cephalad to the forelimb, moving the forelimb further from the head. The forelimb girdle kept its original position immediately cephalad of the cervico-thoracic vertebral junction (figure 2, number 4). As slithering movements changed to flying and running forelimb (shoulder) the girdle drifted further caudad to lie superficial to the thorax.

This gave better anchorage of shoulder girdle muscles. The shoulder girdle and its muscles however kept their cervical nerve supply. The shoulder girdle also retains some rudimentary muscular connection to the head (sternocleidomastoid muscle, levator scapular muscle) with nerve supplies to those muscles from the upper cervical vertebrae. Between species there is great shoulder girdle *form* variation and the human is one of very few species that has a clavicle.

Another way of understanding the development of the shoulder girdle is to see how bones develop embryologically relative to each other. (Reference book II and III). There are two major embryological skeleton portions; (1) the exso-skeleton, and (2) the endo-skeleton. The exso-skeleton in humans forms mainly hair and teeth. The human boney skeleton is entirely endoskeleton.

There are two endoskeleton bone types. Most bone is formed by ossification of pre-existing cartilage and is called *endochondral bone*. The other is *periosteal bone* or membrane bone and is formed by

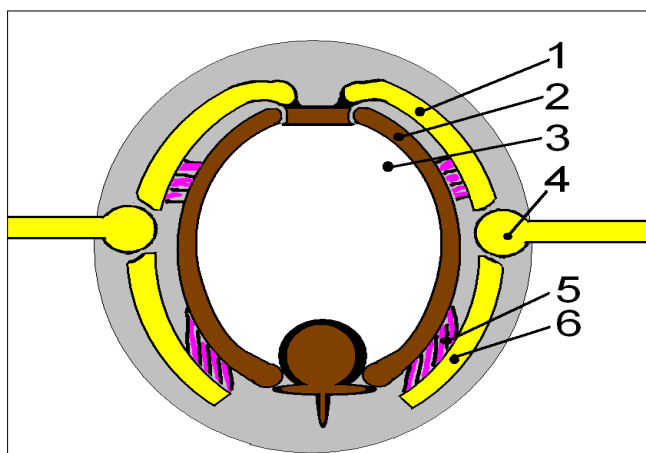


Figure 3. Human axial and upper appendicular skeletons in section.

Key;

- 1 = clavicle
- 2 = rib, attached to sternum to anterior and to the vertebral column posterior.
- 3 = pleural (“visceral”) cavity
- 4 = Humerus head
- 5 = muscles attaching shoulder girdle to thorax, e.g. latissimus dorsi
- 6 = scapular

ossification in a membrane. In humans there is only one periosteal bone, the clavicle.

The skeleton is developmentally divisible into (i) the axial skeleton, (ii) the appendicular skeleton, and (iii) the visceral skeleton. The axial portion includes the skull, and spinal column. The ribs, sternum, jaw and visceral skeleton (ribs) are the “ventral arch” skeleton. In animals higher than fish the ventral arch skeleton is regarded as part of the axial skeleton.

See figure 3. The visceral skeleton (ribs, part 2) develops anterior to the vertebral column and joins to it posteriorly. The appendicular skeleton (parts 1, 4, 5, and 6) develops in a plane superficial to and separate from visceral skeleton. The appendicular skeleton (the shoulder girdle and arm) as discussed earlier and is entirely separate from the true axial skeleton.

Figure 3 also demonstrates how the appendicular skeleton develops in a plane superficial to that of the visceral skeleton. The paired shoulder girdles (left and right) form a segment circle lying anterior (ventral) to the axis of the vertebral column. The circle is incomplete being segmented into left and right half circles. Furthermore the two side half circle segments are in turn subdivided into quarter circle anterior or dorsal (scapular) and posterior ventral (clavicle) parts. Those parts can also be divided into pre-axial and post axial halves that originally lay cephalad and caudad in their primitive original forms.

There is tremendous variation across species in which bony element is well developed or rudimentary. In the chicken the clavicle and interclavicular ligament are fused to form the single wish bone. No four legged animal has a clavicle. All land living animal have a well developed scapulas.

The shoulder girdle is attached to the axial skeleton only by single sternoclavicular joint and muscles (e.g. latissimus dorsi, and pectoralis muscles etc.). The shoulder girdle is very mobile and pivots in all directions about the sternoclavicular joint.

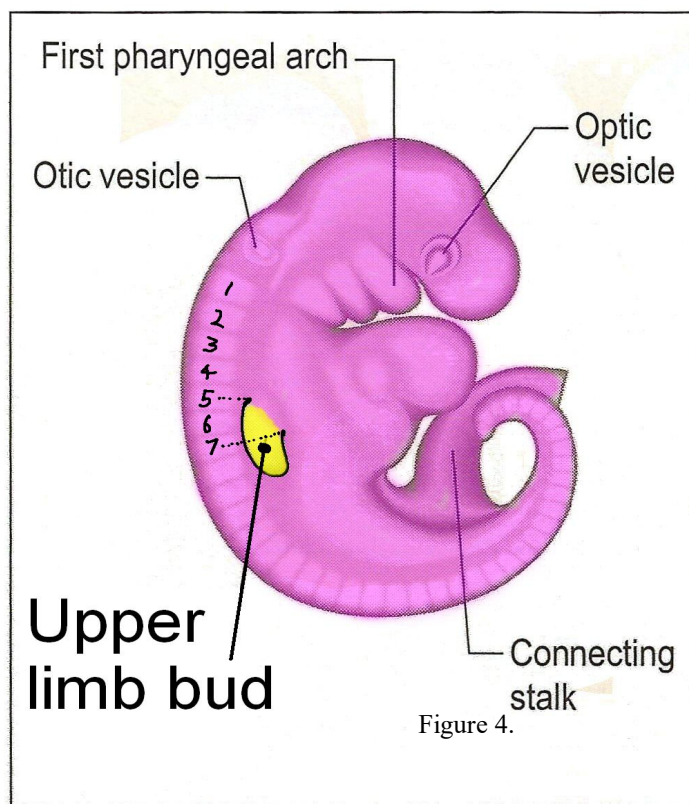


Figure 4.

The fetal upper limb bud (figure 4.) appears at 4 weeks fetal life and develops at the level of C5-6-7 from whence its nerve supply comes. The elements of the upper limb bud are the shoulder girdle, the upper arm, the lower arm and the hands. The human shoulder girdle has three elements; (i) the scapula to posterior, the glenohumeral joint and upper humerus to lateral and the clavicle to anterior.

Every bone, muscle and other tissue element of the *shoulder girdle* will derive its nerve supply from its fetal origin of C-5-6-7 with limited exception. Only the most post axial part of the arm and hand gets a C8 T1 nerve supply and the most pre-axial muscles (levator scapula and sternocleidomastoid) gets a C3-4 nerve supply.

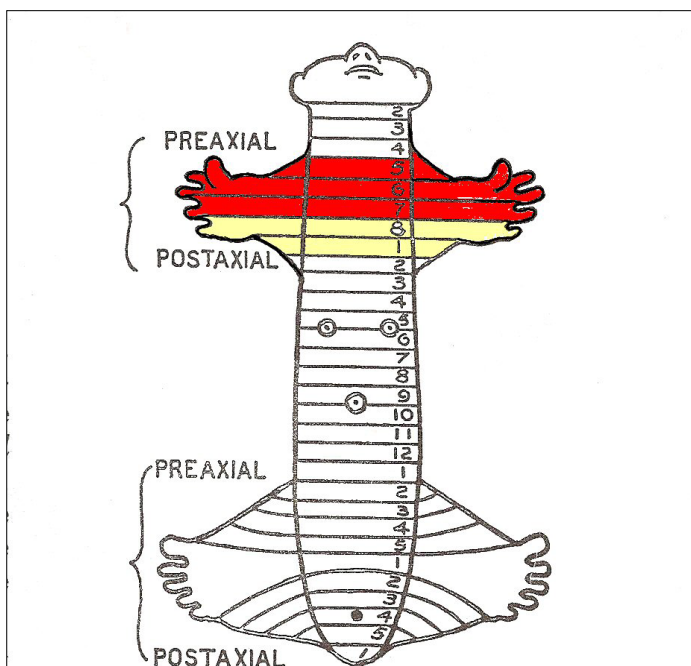
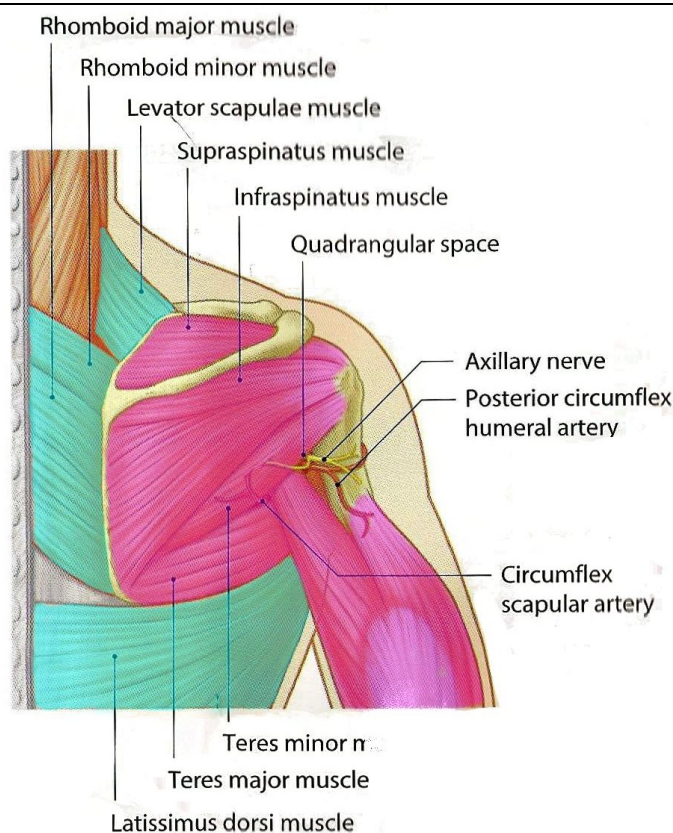


Figure 5. Scheme of primitive nerve distribution. (after Purves-Stewart)



Scapular muscles (posterior view)

CONCLUSION; The human shoulder girdle despite being found to the side of the upper thorax is neck (cervical) derived tissue and is fully cervical in nerve supply even though they may find attachment to the chest. This leads to the formation of “dermatomal sandwiches” where the outermost tissue (skin and fat) have a thoracic origin, the immediate underlying bone and muscles have cervical nerve supplies and deep to that the ribs and intercostal muscles have a thoracic nerve supplies again. Dermatomal sandwiches require multiple nerve blocks to anesthetized adjacent tissues with nerve supplies from far separated nerve roots via different nerves to achieve full anesthesia for one surgical incision. The dermatomal sandwich is best seen in front of the chest about the pectoral muscles and behind the chest over the body of the scapular.

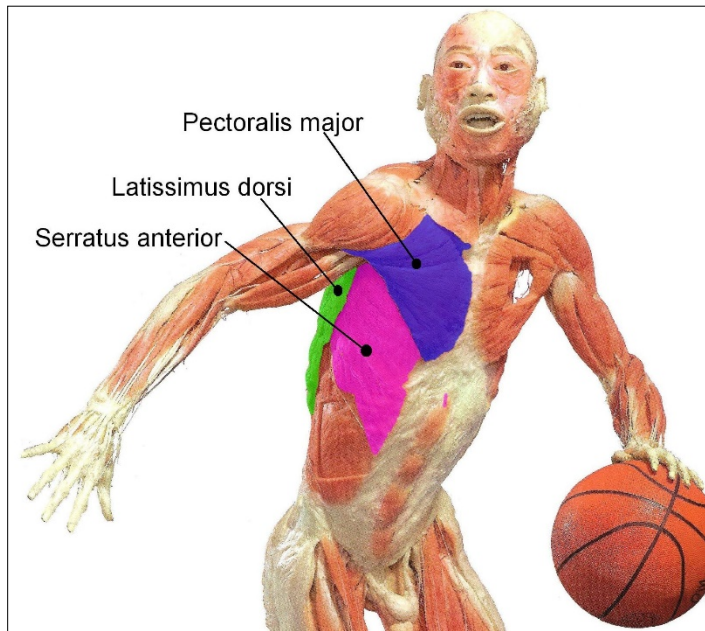
MUSCLES OF THE SHOULDER GIRDLE

The muscle can be categorized into three groups;

1. Those that attached proximally to the scapular and clavicle and distally to the arm. These are subscapularis, infraspinatus, supraspinatus and deltoid muscle. Nerve supply is the brachial plexus.

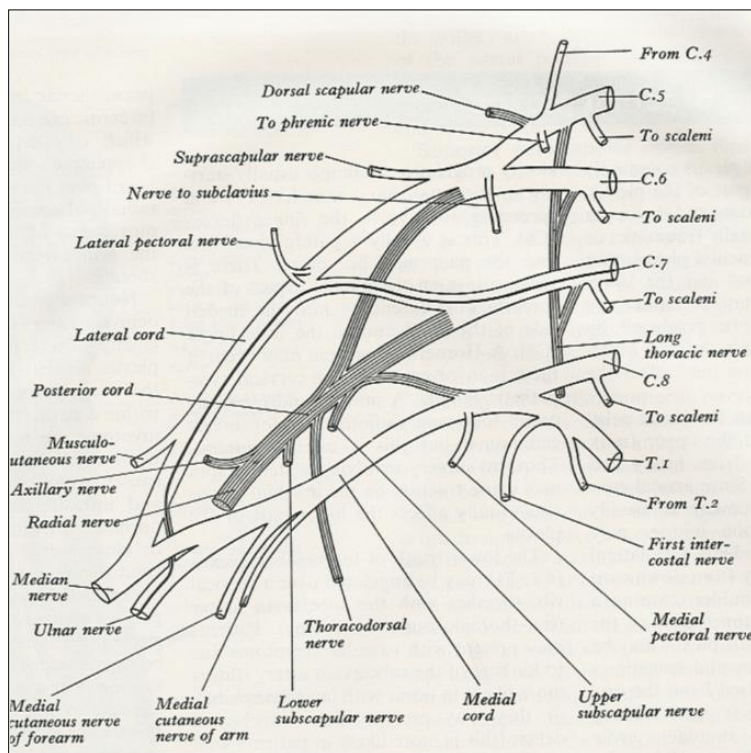
2. Those that attach proximally to the axial skeleton and distally to the scapular and clavicle. These attach the shoulder girdle to the axial skeleton and are not seen as shoulder muscles by the uninformed. Nerve supply is from the brachial plexus. These are mainly the Rhomboids muscles (dorsal scapular nerve), latissimus dorsi (Thoracodorsal nerve), and serratus inferior (long thoracic nerve).

3. Those that attach the head to the shoulder girdle. These get their nerve supplies from above the brachial plexus roots (C3 and 4). These are the trapezius, levator scapulae and sternocleidomastoid muscle mainly.



NERVE SUPPLY OF THE SHOULDER GIRDLE.

Nearly everything is supplied by the brachial plexus with some exceptions. The exceptions are the spinal accessory nerve (trapezius), Dorsal scapula nerve (Rhomboids), and direct segmental nerve supply of levator scapulae. All skin on the superior aspect of the shoulder, i.e. over the clavicle and on top of the acromion is supplied by C4 roots of the superficial cervical plexus.



TYPES OF SHOULDER GIRDLE SURGERY

Surgery of the shoulder joint can be classified as;

1. Gleno-humeral joint and related surgery.
 - Shoulder arthroplasty
 - Shoulder joint arthroscopy
 - Surgery for acromial impingement
 - Surgery for rotator cuff tears
 - Surgery for recurrent dislocation
2. Clavicle surgery
 - Clavicle shaft fracture - repair
 - Sternoclavicular joint dislocation repair.
3. Scapula surgery
 - Scapula fracture with scapula-thoracic dissociation repair (Fracture the length of the scapula in a vertical plane)
 - Scapula fracture with gleno-humeral joint involvement repair
 - Surgery for winged scapular (scapulothoracic arthrodesis, and scapulopexy)
4. Other
 - Forequarter amputation

Surgery for Acromial impingement, rotator cuff tears, and acromioclavicular plasty

Brachial plexus traction is more likely in a lateral decubitus position with arm traction. This increases the risk for nerve injury if this position is used.

1. **SAD** (subacromial decompression) is done arthroscopically alone or open with a rotator cuff repair via a deltoid splitting incision. If the incision exceeds 5 cm from the acromion towards distal it can cut axillary nerve fibers.
2. **2. RC repair** (rotator cuff) can be done open or arthroscopically. The arm is commonly manipulated and traction used. Open procedures cause 400 ml blood loss.
3. **Repair AC joint dislocation.** A rare surgery. Incision over clavicle (lateral 1/3) and AC joint. Technically a complex operation with risk of brachial plexus injury and subclavian vessel damage.

Nerve injury risks;

- Axillary nerve 1-2%
- MCN 1-2%
- Brachial plexus – variable
- Suprascapular nerve – especially with rotator cuff mobilization

Shoulder instability (MDI); multidirectional instability.

Types are (i) atraumatic associated with laxity syndromes and psychiatric disorders, and (ii) traumatic disorders.

The typical traumatic dislocation is to anterior, is recurrent, and involves young patients with an antero-inferior glenoid rim capsular-labrum avulsion (Bankart injury). Dislocations over 50 years of age mostly include rotator cuff tear, and fractures which may need independent repair. A pure “old person” one reduced does not need surgery and seldom re-dislocates.

The Bankart repair for recurrent anterior-dislocations uses a delto-pectoral groove incision. Raw (decorticated) bone is needed to reattach the dislocated joint brim and with the deltoid muscle incision bleeding can be abundant. Injury of the CMN (traction of the coracobrachialis muscle. and axillary is a high risk. The arthroscopic Bankart repair has one port come in from posterior that may touch on a thoracic dermatome at its skin insertion point. Beach chair position is standard.

Posterior dislocations have similar type of glenoid labrum repair done involving decortication of bone and suture anchors through drilled holes, but from posterior in the patient lateral decubitus position. The posterior incision passes between infraspinatus and teres minor.

Axillary nerve injury can occur in 15% of patients, and is pre-existing in some.



ARTHROSCOPIC SHOULDER SURGERY

GENERAL INFORMATION;

Procedures include subacromial decompression (SAD), distal clavicle resection (Mumford procedure), debridement (synovitis, labral tear, infection), rotator cuff repair, ant capsule labral repair for recurrent dislocation, (Bankart repair), capsular plication (MDI multidirectional dislocation, capsular release for frozen shoulder and repair of SLAP lesions (sup labral ant-post tears).

Indwelling joint catheters for local anesthetic infusion have been associated with chondrolysis.

The patient position is either lateral decubitus or beach chair position. Nerve injuries rare but higher in the lateral decubitus position. Fluid extravasation (it has epinephrine in it) is common and is painful.

General anesthesia is used. Interscalene block provides total analgesia. Procedures can be done awake but are difficult to handle for the surgeon, anesthesiologist, and the patient. It is an uncomfortable patient position and the manipulation of the shoulder girdle is unpleasant. General anesthesia is recommended in all but exceptional cases.

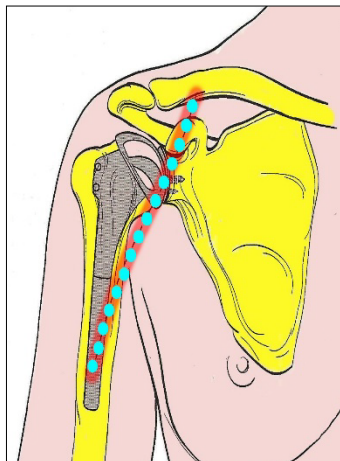
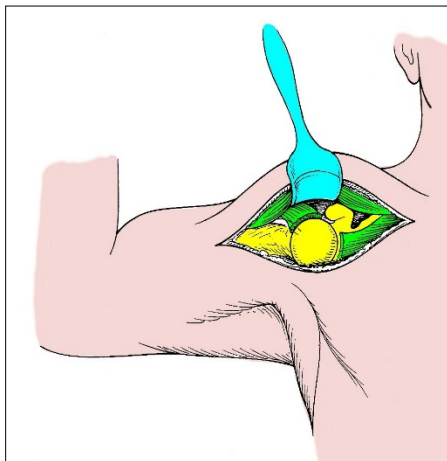
INSTRUMENT INSERTION PORTALS

There are three essential port insertion sites; anterior, superior and posterior. A lateral port is used for subacromial surgery. The posterior port is usually the primary entry port that is used to assist placement of the other two ports. The typical posterior port is inserted 2 – 3 cm inferior and 1 cm medial to the posterolateral tip of the acromion. If posterior plication is planned or second posterior port then the port can be 5 cm inferior to the posterolateral tip of the acromion. This is important as pain from the port can occur despite a functional interscalene block because the skin incision can be in a thoracic dermatome. The anterior and superior port insertion point are covered by large volume interscalene block. A small volume (under 25 ml) interscalene block may fail to block the superficial cervical plexus C4 root and it is then also possible superior port skin incision could be un-anesthetized. The superior port is inserted just medial to the acromion immediately anterior to the clavicle and the port is directed to lateral over the body of the acromion.

SHOULDER ARTHROPLASTY SURGERY

INTRODUCTION

This procedure is common especially amongst the elderly. The typical incision is in the deltopectoral groove although sometimes the anterior deltoid muscle is split.



The coracobrachialis muscle from the coracoid bone to mid-medial humerus marks the safe surgical boundary on its lateral side. The axillary nerves and vessels lie to its medial.

Nerve injury can occur; (1) to the *musculocutaneous nerve* lying within the coracobrachialis muscle from excess re-traction, (2) excess dissection inferior to the glenoid can injure the *axillary nerve* as it passes below there to posterior, (3)

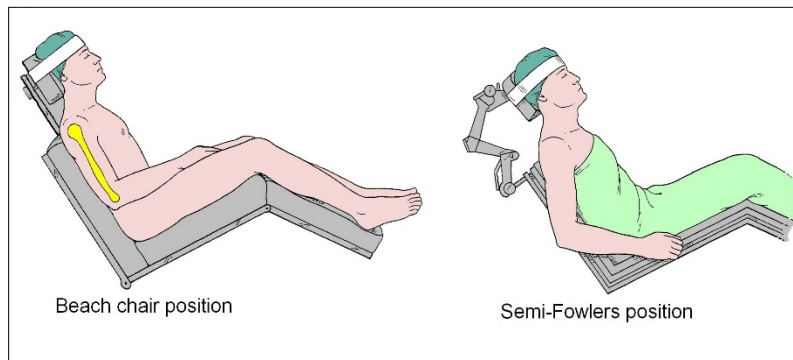
excess soft tissue release superior to the glenoid can injure the *suprascapular nerve* 2 cm behind the glenoid, and (4) overall excess arm traction can injure *any brachial plexus* component. Most post surgery-anesthetic neuropathies resolves within 6 months.

This surgery is done in the beach chair position or Semi-Fowlers position and excess neck extension must be avoided in the kyphotic elderly person. A strut is placed against the rib-cage on the side of the surgery to prevent the patient being pulled off the table during surgery. The strut can cause injury to the chest or to the long thoracic nerve if traction is severe. Rheumatoid arthritis is the most common

co-morbidity with shoulder arthroplasty, and more so than with lower leg arthroplasties. Rheumatoid arthritis has an independent association with increased neuropathy. This can confuse pin-pointing blame after any discovered neuropathy after surgery and anesthesia.

The commonest nerve injury is to the axillary nerve and permanent injury more likely follows revision surgery. The injury is devastating. Management is (i) test the nerve post surgery to make the

diagnosis, (ii) if there is no recovery at 3-6 weeks perform EMG three monthly, (iii) explore the nerve if no EMG evidence of recovery exists. Removal of extruded cement may help recovery



For post surgical analgesia use an interscalene block with perineural infusion.

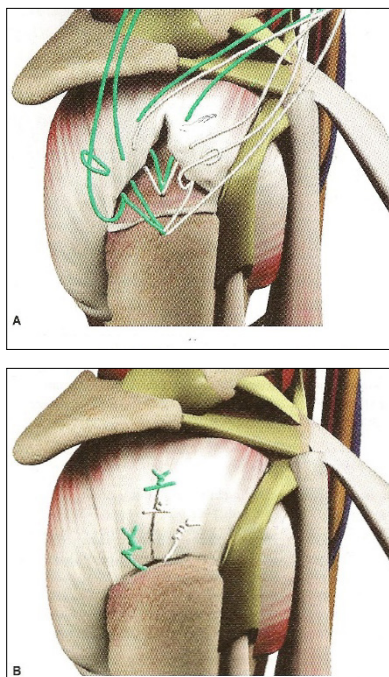
FROZEN SHOULDER SURGERY

Adhesive capsulitis causing frozen shoulder has features of complex regional pain syndromes and there are a small number of patients who develop neuropathic pain after surgery. Surgery is arthroscopic capsulotomy.

SUB-ACROMIAL DECOMPRESSION (S.A.D.)

There is one opinion that these patients have special risk for nerve injury with nerve block based on a personal anecdote but that is contrast to other anesthesiologists' opinion with different experiences. There is also an absence of scientific literature evidence support avoidance of nerve blocks with SAD.

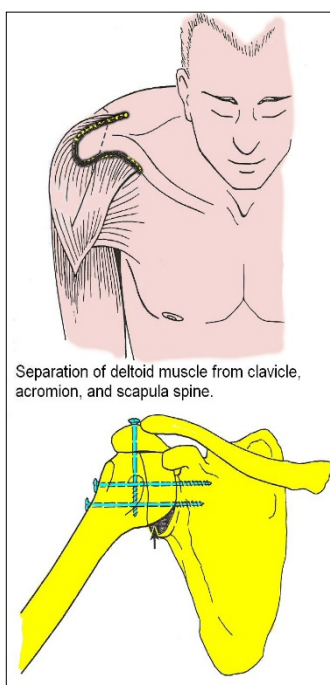
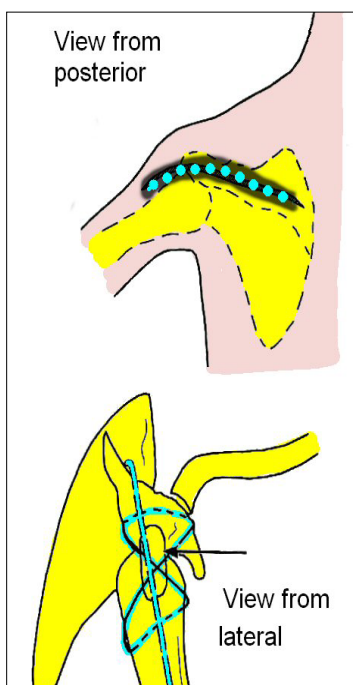
ROTATOR CUFF REPAIR



This is a very painful procedure and interscalene block to accompany the general anesthetic is recommended.



GLENO-HUMERAL ARTHRODESIS



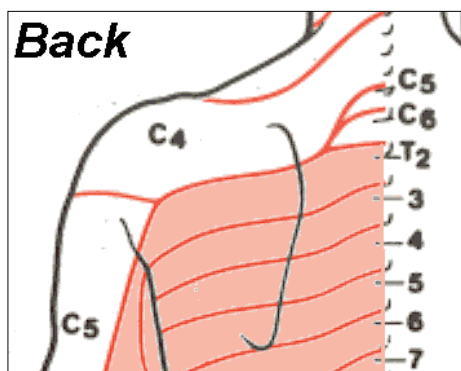
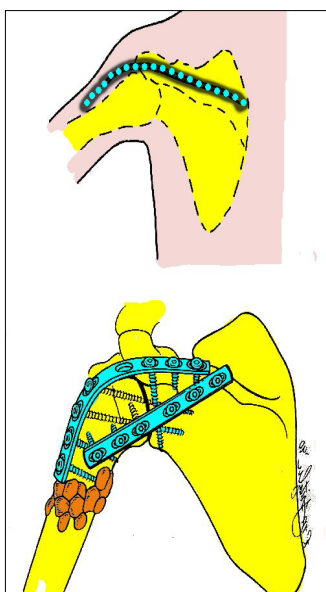
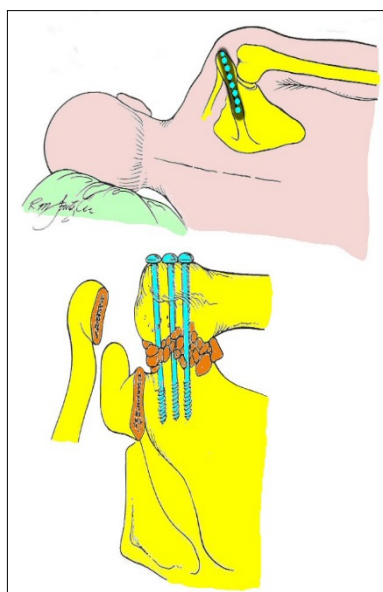
This is indicated for failed shoulder arthroplasty with substantial bone loss, bone infection, multiple failed arthroplasties, and severe loss of shoulder muscle function in particular of the rotator cuff.

There are various incisions; (i) supero-lateral approach trans-deltoid separating the deltoid muscle from its clavicular, acromial and lateral scapula attachments, (ii) posterior incision along the scapular spine separating both the trapezius and deltoid from the spine, and (iii) postero lateral incision along the scapular spine separating both the trapezius and deltoid from the spine then running lateral onto the humerus splitting the deltoid muscle.

Nerve injury reported as consequence of surgical arthrodesis is very rarely reported.

Interscalene block with general anesthesia is recommended.

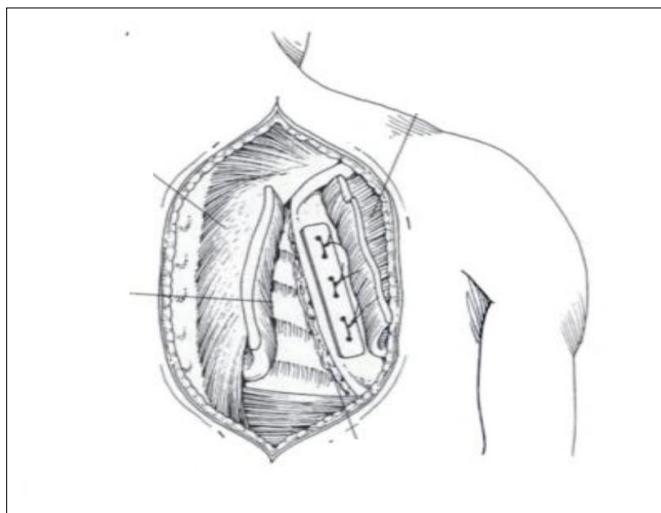
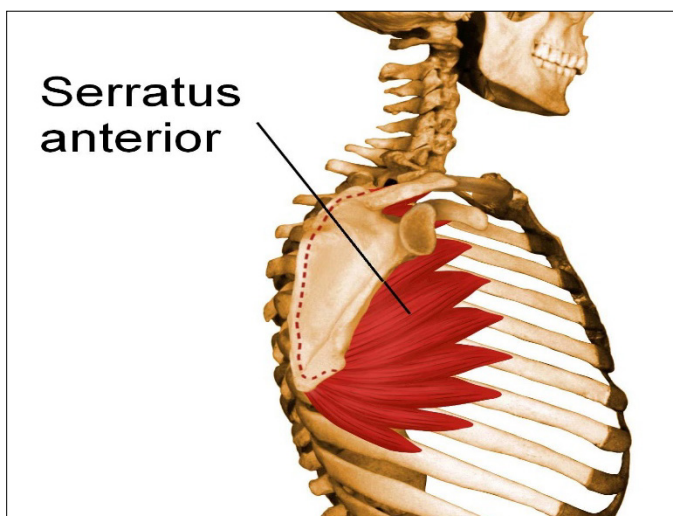
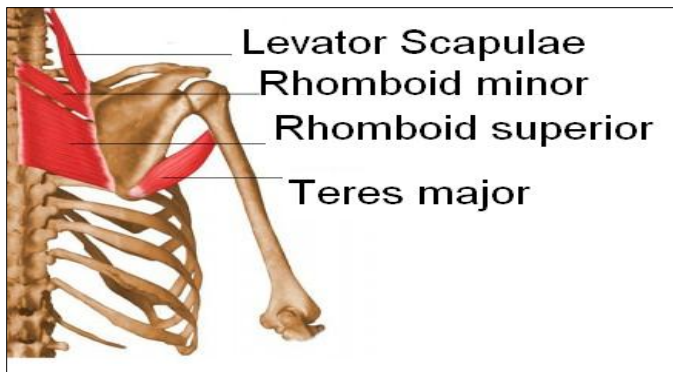
If a posterior approach is used to the arthrodesis then the skin incision reaching into thoracic dermatomes will need separate local anesthesia. Thoracic T3 paravertebral block is an option but skin infiltration is easiest and reasonably effective. Use 10 to 15 ml 0.25% bupivacaine.





SPECIAL SHOULDER GIRDLE SURGERIES

1. SCAPULOPEXY AND SCAPULOTHORACIC ARTHRODESIS



The scapula is held flat against the chest mainly by the serratus anterior muscle attaching to the deep aspect of the medial edge of the scapula, as well as by the Rhomboid muscles attaching also attaching to the medial edge of the scapula and pulling the scapula direct to medial. There are a large number of illnesses and injuries of the nerve supply of these muscles leading to winging of the scapula and causing considerable disfigurement and disability to the patient.

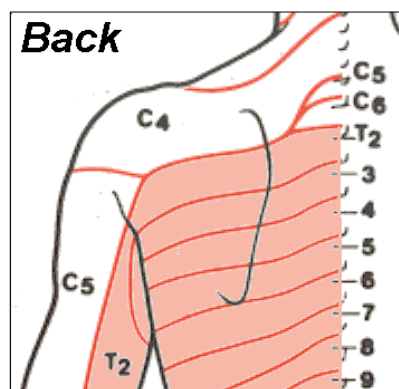
SCAPULOPEXY is an older operation where slings are passed through medial aspect of the scapular and the adjacent ribs to hold them the scapula against the thorax.

SCAPULOTHORACIC ARTHRODESIS is development of that first procedure where the scapular medial deep aspect and the adjacent ribs are bone grafted to each other. The bones are held position wires or bolts through the ribs and the scapular.

Both these surgeries involve a posterior parasagittal incision about 6 to 10 centimeters from the midline through skin and about 10 to 20 centimeters long over the medial aspect of the scapula. The rhomboids muscles will be briefly separated from the scapula to reveal the ribs.

Full analgesia will require;

1. Interscalene block (roots C5, 6, 7) for the scapular and its involved muscles that have proximal attachments to the bone (infraspinatus, supraspinatus and subscapularis)
2. Thoracic paravertebral block (T2 to T7) for the ribs, intercostal muscles and skin.



General anesthesia will be needed as well for the surgery. Be alert for respiratory difficulties intra-op and post-op resulting from a pneumothorax, from loss of chest cage mobility in the surgical side, and from pain splinting. Most generally healthy patients tolerate the procedure very well except for the pain which is severe.

The interscalene block is best maintained with a standard infusion of local anesthetic via perineural catheter for the duration of the hospital stay. The first dose can be 25 to 35 ml 0.75% Ropivacaine. This is the most important part of the nerve blocks.

The thoracic paravertebral block is ideally maintained with an infusion of 10ml / hour of 0.2% ropivacaine via a catheter placed at the mid zone (T4 best or T3 second best). Initially single shot paravertebral blocks can be done at T3 (5ml) and T6 (5 ml) to supplement the catheter (T4) first dose of 15 ml of 0.75% ropivacaine.

Despite this there is still a 5% chance that analgesia will be less than 100% but it should still be satisfactory. The patient who has only had an interscalene block will still need substantial supplementary opioid analgesia. If the thoracic paravertebral blocks are omitted then the skin incision should be infiltrated with 0.25% bupivacaine. This will in total give 80% analgesia but the patient will still need significant opioids and when the skin anesthesia resolves after about 12 to 18 hours a notable increase in pain will occur.

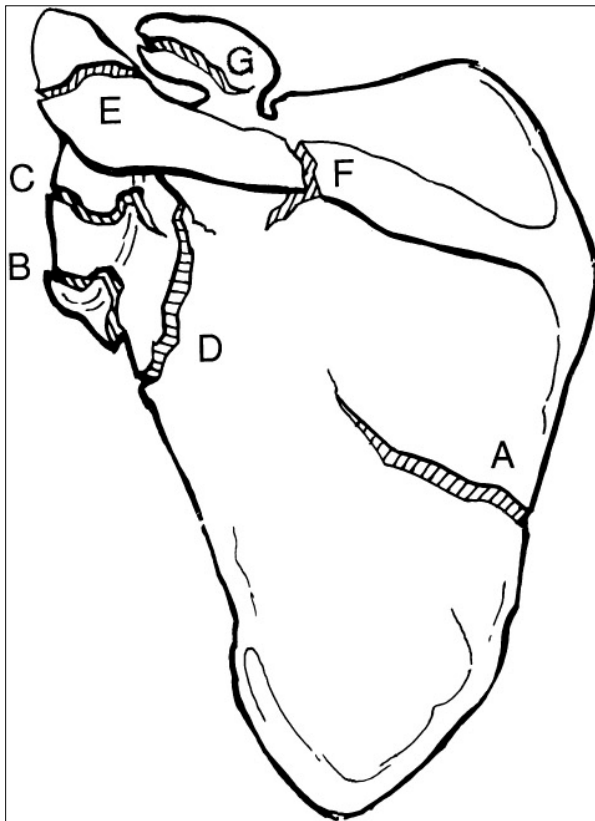
If only single shot thoracic paravertebral blocks are done (together with the interscalene block) the patient may awaken from surgery totally pain free or close to that. Thoracic single shot nerve blocks do not last very long and the patient will experience a big increase in pain from the skin and rib surgery between 6 and 10 hours after the surgery.

Multimodal analgesia must always supplement the regional anesthesia plan regardless. If tolerable by the patient, NSAIDS and acetaminophen, and a dose of intra-operative ketamine (0.5 mg/kg) should be a minimum part of the multimodal analgesia.

The interscalene block should never be omitted. Using no regional anesthesia is cruel for these patients.

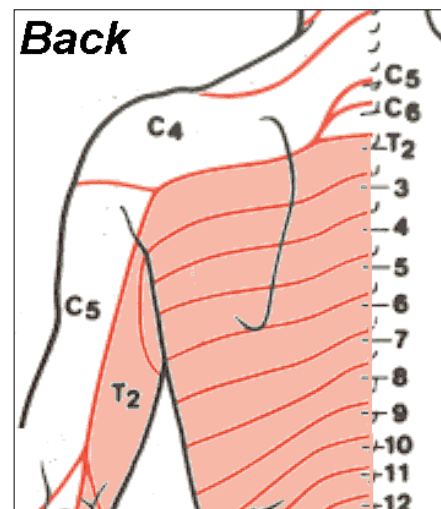
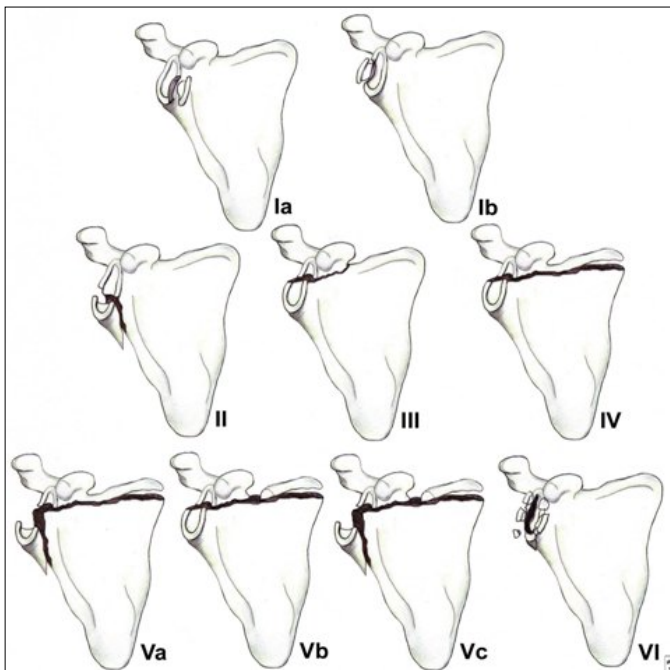


2. SCAPULA FRACTURES



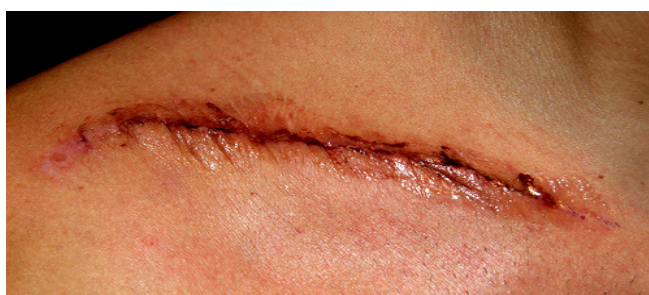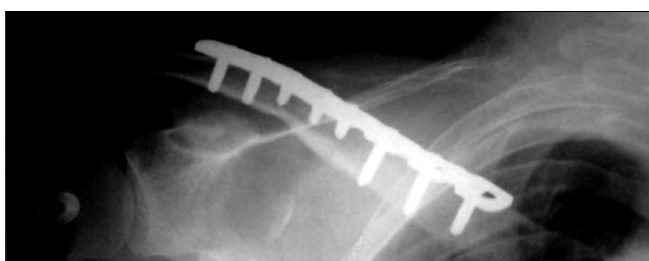
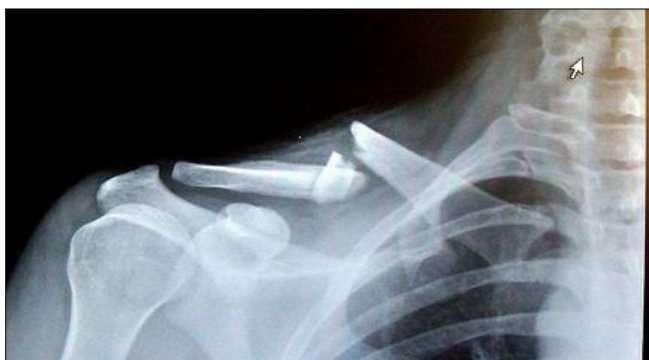Patients tend to be young and injuries can be minor athletic trauma or extreme deceleration trauma. Expect chest and rib injuries to accompany the scapula fracture. A scapular fracture does not need surgery unless (i) it involves the glenoid cavity making it an intra-articular fracture, or it is extreme and causes scapular-dissociation with wide fracture opening. Acromio-clavicular separation is only repaired if the acromion and or clavicle is fractured as well. Most scapula fractures are not repaired.

If a scapula fracture is repaired a general anesthetic is used. Analgesia is provided by an interscalene block. It is necessary to establish from the surgeon the skin incision. If the skin incision intrudes into the thoracic dermatomes either a skin local anesthetic infiltration is needed after surgery in addition to the nerve block, or thoracic paravertebral block corresponding with the incision is needed (typically at T3 or T4). The skin infiltration is perhaps the best for ease of insertion and safety. Use multimodal analgesia with the nerve blocks.





3. CLAVICLE SURGERY



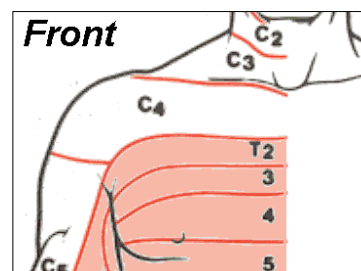
There are two surgical groups here. The first involves clavicle shaft fractures. The second involves sternoclavicular-joint dislocations. Anterior dislocations are not always operated unless a source of persistent discomfort. Posterior dislocations can be associated with airway compression and are nearly always operated and rarely even as an emergency. Isolated clavicle fractures are less often operated, but if there is an associated scapular fracture they are more likely repaired.

General anesthesia is needed for the surgery and vigilance must be kept for unplanned injury to pleura and major blood vessels in the area. Deaths have occurred from subclavian artery injury and bleeding.

Regional anesthesia for analgesia is easy to supply. A standard interscalene block (C5, 6, 7) fully supplies analgesia to the ENTIRE clavicle including its part of the sternoclavicular joint. The minuscule fraction of the sternal aspect of the joint is supplied by T1 and will be covered by any small degree of interscalene block spread to reach the T1 portion of the brachial plexus. The skin over the clavicle for distance of 2 to 5 centimeters caudad is supplied by the C4 root portions of the superficial cervical plexus. The superficial cervical plexus however does not need to be nerve blocked separately. A full interscalene dose of 40 ml of 0.75% ropivacaine consistently achieves cephalad paravertebral spread to include the C4 and C3 roots. A micro-volume (10 to 20 ml) interscalene block could however fail to anesthetize the skin and half of the sternoclavicular joint.

In summary; **any clavicle surgery only needs a standard 35 to 40 ml interscalene block.** Warn the patient of the

arm paresis that will accompany analgesia. Generally a single shot block is sufficient as by the time the block resolves, a good multimodal analgesia strategy that overlaps with the duration of the nerve block is usually satisfactory. It is however perhaps ideal to maintain the interscalene block overnight with perineural infusion should the patient remain in hospital for the night.



4. FOREQUARTER AMPUTATION

These patients need both a T3-4 paravertebral nerve block catheter and an interscalene nerve block catheter.

5. SHOULDER DISLOCATION REPAIR UTILISING THE LATISSIMUS DORSI MUSCLE

The incision to harvest the latissimus dorsi muscle for the shoulder repair descends below the shoulder joint for 10 to 25 centimeters approximately along the posterior axilla line. An interscalene block is needed for the bulk of the surgery. Single shot paravertebral blocks at T3, 5 and 7 of 10 ml each is highly effective for analgesia of the latissimus dorsi muscle harvest. An alternate is to infiltrate the latissimus dorsi harvest incision with local anesthetic but this seems to be ineffective by comparison. Doing an interscalene alone will still result in a patient with severe pain immediately after surgery. Utilize a multimodal analgesia approach to balance out the nerve blocks.

6. SHOULDER SURGERY WITH CONTRAINDICATION TO INTERSCALENE BLOCK

An example is morbidly obese male with asthma, obstructive sleep apnea and chronic obstructive airway disease. This patient will not accompany the phrenic nerve block that accompanies all interscalene blocks. Equally this patient will not tolerate a large amount of opiates after surgery. The patient is undergoing open rotator cuff repair which is very painful.

Therefore there is pressing need to use regional anesthesia that does not threaten the phrenic nerve. Regional anesthesia options are;

- Intra-articular local anesthetic; not recommended due to poor efficacy and risk of cartilage damage.
- Infiltration of incisions with local anesthetic; not recommended due to poor efficacy.
- Selective nerve blocks of
 - Suprascapular nerve
 - Pectoral nerves
 - Axillary nerves
 - Superficial cervical plexus C4 derived nerves.

This readily achieved as follows. The superficial cervical plexus can be blocked in the neck in the classic position. The axillary and pectoral nerves can be blocked with an infraclavicular superior cord block. The suprascapula nerve block can be blocked with number of techniques, including its selective identification using ultrasound guidance in the supraclavicular region in its relationship to the omohyoid muscle and confirmed with nerve stimulation.

Special anatomy information;

The shoulder joint receives in capsular nerve supply as follows;

1. Suprascapular nerve; the superior and posterior two thirds.
2. The axillary nerve; the inferior quarter.
3. The pectoral nerves supplies an anterior small portion

The skin about the shoulder is supplied by the axillary nerve and the supraclavicular C4 nerves.

COMPLICATIONS OF SURGERY AND NERVE BLOCKS FOR SHOULDER GIRDLE SURGERY

It is unusual for two radically different medical specialties to simultaneously performing major and potentially life changing or even lethal interventions on a single patient. That is the nature of surgery and anesthesia. Furthermore, there are a large number of complications that both medical specialties could cause to the patient. When such complications arise, it is often unclear as to the etiology of the complication and the mechanisms how it developed. It is human nature to want to disbelieve oneself is responsible for an unanticipated undesired patient consequence of one's own actions. Anesthesiologist are invariably the first line of blame by the surgeon, who often is the one to discover the patient complications. Predominantly the complications are nerve injuries.

A good anesthesiologist thus will know as much as possible about anesthesia and nerve block associated complications. This will lead to hopefully both (i) better avoidance of complications, and (ii) earlier recognition and treatment of complications. That is good for the patient. The third benefit will be to

be better able to defend one self medico-legally and identify likely surgical etiologies, when such are present.

The most common or most serious complications associated with surgery and anesthesia with nerve blocks for shoulder girdle surgery are the following.

1. Cerebral and spinal cord ischemia¹. Pohl described four case reports where the patients all suffered cerebral or spinal cord ischemia after shoulder surgery in the sitting position. The leading risk factor blamed were mild hypotension probably most caused by the sitting position, or beach chair position. The authors also point out that the cerebral perfusion pressures would have been 8 to 23 mmHg lower than that measured in the arms. The problem may have been compounded by unrecognized severe neck flexion or moderate neck hyperextension compressing vertebral arteries. No nerve blocks were performed. Avoid hypotension in the sitting position for shoulder surgery. Keep the head and neck in a neutral position for the patient. This subject was reviewed in 2014, with similar conclusions².
2. Local Anesthetic Toxicity. See other texts for more information.
3. Phrenic nerve block or injury. See other texts for more information.
4. Horner syndrome. This is due to block of the sympathetic chain and occurs in 40 to 70% of patients receiving an interscalene block.
5. Hoarseness from a recurrent laryngeal nerve block following an interscalene nerve block. This occurs in 5 to 17% of patients.
6. Pneumothorax. This has become very rare since the use of ultrasound guidance for needle placement with interscalene block, but not totally eliminated.
7. Vertebral artery injection with interscalene block. Ultrasound needle guidance has eliminated this problem.
8. Total spinal block with interscalene block. Ultrasound needle guidance has eliminated this complication.
9. Spinal cord injury with interscalene block. Ultrasound guidance had eliminated this complication.
10. Cervical epidural block. Ultrasound needle guidance has eliminated this complication.

DO SHOULDER NERVE BLOCKS OFFER BENEFITS FOR PATIENTS UNDERGOING SHOULDER GIRDLE SURGERY?

A 2014 study of a billing data base by Stunder and Memtsoudis retrospectively reviewed 17 157 patients who had undergone shoulder arthroplasty. Twenty one percent of the patients received regional anesthesia added to their nerve blocks. Those patients received benefits, primarily of improved postoperative analgesia. In addition to the primary benefit of analgesia, regional anesthesia has many secondary benefits (see other reviews for expanded discussion of this). Most notably there was no evidence of disadvantage from the addition of the nerve blocks. Use of blood, admissions to ICU, duration of hospital stay and general complications were identical whether nerve blocks were used or not in these study patients. In agreement with other studies³, there was no suggestion of nerve blocks causing nerve injuries.

There is thus good reason to utilize regional anesthesia, with general anesthesia for shoulder girdle surgery. In selected cases awake surgery can also be performed, under regional anesthesia alone.

WHAT ROLE DOES LIPOSOMAL BUPIVICAINE HAVE TO PLAY IN SHOULDER SURGERY?

There is tremendous commercial drive to bring slow release liposomal bupivacaine (SRLB) into use in shoulder surgery, to replace standard local anesthetic peripheral nerve blocks. The SRLB is expensive and the marketing company is heavily invested in it. There are many paid speakers proselytizing the drug.

The USA Food and Drug Administration department (FDA) initially restricted the company marketing liposomal bupivacaine from claiming 72 hours of benefits to only 48 hours. That was based upon a judged view that there was insufficient scientific evidence justifying the claim. The company took an unprecedented legal challenge against the FDA, and an altered statement



wording was introduced by the FDA. The FDA very recently permitted liposomal bupivacaine be advertised for use in perineural injections in shoulder surgery. Near immediately, Dr. Gadsden, a company remunerated anesthesiologist privately released partial study results at a conference claiming this would be a “game changer” use of liposomal bupivacaine. The study is not yet available for open academic scrutiny. Critics who have seen partial results were skeptical and pointed out a high level of inconsistency in outcomes with few patients achieving high grade analgesia. Notably the very slow onset of any discernable effect of the liposomal bupivacaine required the nerve block be performed well ahead of the surgery in time. There are logistical and cost implications in that, the very thing the company marketing for infiltration use of periarticular SRLB highlighted as disadvantage of nerve blocks. The marketing claim was *then* that infiltration SRLB’s advantage was that it could eliminate the logistical and costs requirements for performing a nerve block ahead of surgical time. The term *game changer* is already being highlighted in non-peer reviewed journalistic marketing on this drug. The core fact, is that there is not yet, (June 2018) validated scientific evidence for that claim.

Let us review the available scientific evidence.

Encapsulated bupivacaine has been investigated for 25 years⁴. It failed to find a market application until recently with the launch of Exparel^(r) liposomal bupivacaine. A 20 ml solution contains 266 mg of bupivacaine. Assuming that drug is released evenly and completely, then it is released it at a rate approximating a 5ml per hour infusion of a 0.001% bupivacaine solution. That is an unprecedented low dose with which to initiate a nerve block. That also is a solution strength and dose that is likely to only block the very most thin of nerve fibers and unmyelinated fibers. It will likely fail to block thicker fibers like the A-beta fibers which can briefly also play a role in pain transmission. Study observations fit that predicted result.

The first question is, is the drug efficacious in inducing analgesia? There are to date very few studies on shoulder surgery and liposomal bupivacaine. One weak study, that was neither randomized nor prospective, looked at a total of 55 patients having shoulder arthroplasty⁵. Liposomal bupivacaine was injected into the study group as a surgical wound infiltration technique at the end of surgery. There were two groups, with a double drug change. Good research with a double drug study normally requires four study groups. The control cohort received multiple analgesia drugs and an interscalene block before the end of surgery. The article provides no information on the interscalene block technique. Thus, it cannot be guessed as to the duration of total analgesia that would have resulted from the interscalene block. It is against the background interscalene block that the liposomal infiltration bupivacaine must stand. Also, one cannot assess the risk of local anesthetic toxicity from the double block without more information. The study cohort received everything the first group got, plus periarticular ILB and 10 mg IV dexamethasone. They tried to stratify the patients into who used perioperative opiates and who did not. Only the subgroup who had been on pre-operative opiates demonstrated statistical suggestion in this very bad designed study that ILB combined with IV dexamethasone and any analgesia effects. There is no suggestion which of the two study may have contributed to the suspected better analgesia. Also, it cannot be determined whether LIB only has benefit of IV dexamethasone as added. That study would have been rejected by all reputable journals. Other efficacy studies, mostly for other surgery types do however suggest ILB has some efficacy as an analgesic.

Once efficacy is established the next studies need to answer a lot of questions;

1. How RAPIDLY does discernable analgesia become apparent. Is it within 5 minutes, within 30 minutes or only after 6 to 12 hours.
2. How DENSITY is the local anesthetic block? Is its best analgesia soon after surgery during the worst pain phase total or only partial? High density blocks will also induce loss of skin sensation and motor weakness. Low density blocks risk incompleteness and inconsistency.
3. How RELIABLE is the local anesthetic block? A group average that seems an acceptable pain score improvement may conceal the fact that many of the group only achieved unacceptable results individually. Modern nerve blocks with regular drugs achieve reliability rates of 99% and more. The few failures of modern nerve blocks relate to incongruence in the surgery done and the nerves selected for blockade, also influenced by unrecognized anatomical variations in the nerve anatomy.
4. What is the DURATION of quality analgesia?



5. What is the DURATION OF MOTOR weakness, if any?

This data is presently unavailable for SRLB and shoulder arthroplasty.

The available studies at this date (2018-6-3) include 3 metanalysis studies on the effect of periarticular Infiltration SRLB for shoulder arthroplasty surgery compared to standard interscalene block bupivacaine^{6, 7, 8}. Those metanalyses, fairly similarly, could each only identify 4 or 5 studies of about 350 to 500 patients in total, for review. Of those 5 trials only two were in fact prospective Randomize Controlled Trials (RCTs) studies. Thus, some of the metanalyses fraudulently labeled some retrospective trials prospective randomized. All three metanalyses then claimed equivalence between infiltration liposomal bupivacaine and interscalene block for postoperative analgesia following shoulder arthroplasty. If one however examines only the two RCTs they each found ILB significantly deficient in the first 24 hours after surgery or so. Presently there are three available TCTs.

The one prospective randomized controlled study was by Namdar⁹. The interscalene block group received 30 ml of 0.5% ropivacaine into the brachial plexus. The interscalene block was clinically and statistically very superior for analgesia in the first 8 hours after surgery only. The interscalene block was also significantly superior for least opiates used intraoperatively. The liposomal group only achieved superiority for analgesia by after 24 hours after surgery with a pain score difference of 1 on a 10-point VAS scale.

The second prospective randomized controlled study, by Abildgaard, compared ILB with an interscalene catheter¹⁰. The interscalene group had significantly superior analgesia at all times until about 36 hours after surgery, where the ILB group achieved equivalence for the first time.

The third randomized prospective trial appeared in 2018 but used ropivacaine 0.5% in the interscalene block group¹¹. This trial showed the ropivacaine interscalene group patients had best analgesia for up to 16 hours after surgery. Certainly, a bupivacaine interscalene group would have had four and more hour's analgesia advantage. The ILB group patients only achieved analgesia equivalence with the worn-off interscalene block on the day after surgery onwards.

BREAKING NEWS:

At the ASRA Spring (April) 2019 conference a poster case was presented of a patient who had an interscalene block including liposomal bupivacaine. International and national delegate visitors reported knowledge of a few similar cases. The poster patient experienced an unusually long duration and problematic phrenic nerve block. In this author's career experience of phrenic nerve blocks secondary to standard interscalene blocks that were recognized, the majority were tolerable without need for intubation, and resolved between 2 ½ and 3 1/3 hours after the initial block injection, even though the nerve block to the C5-6 dermatomes was retained 10 to 20 hours. So likely many phrenic blocks, after standard nerve blocks, escape discovery due to being of short enough duration to be mostly resolved by the end of surgery and general anesthesia.

Conceptually, if addition of liposomal bupivacaine suspension to a bupivacaine solution for an interscalene block is capable of extending the duration of the C5-6 portion of the block and its associated analgesia then, the added liposomal suspension if reaching the phrenic nerve can also delay its recovery.

It is well known that the incidence of phrenic nerve block with full volume standard drug interscalene blocks can reach an incidence of 100%. The fact that so few of these patients have clinical problems after completion of surgery and termination of the general anesthetic, is likely due to the fact that the phrenic nerve lying far from the point of injection, is a far component of the entire block. Therefore, the phrenic nerve is only minimally exposed to local anesthetic drug and only achieves milder nerve block for a shorter time, than the nerves more exposed (C5-6 roots) and soaked in drug.

This case report, with this above understanding, is serious enough to advise that liposomal bupivacaine is severely unsafe in peripheral nerve blocks like interscalene blocks, where a critical side effect like phrenic nerve block is possibility.

CASE DISCUSSIONS;

Patient number 1. The patient was 50 years old and morbidly obese. He suffered from obstructive sleep apnea and was the last elective patient of the day to receive a shoulder arthroplasty. The anesthesiologist performed a single shot interscalene block injection of 35 ml of 0.5% bupivacaine. The nerve block was done in a pre-surgery preparation area used for doing nerve blocks. The usual assisting nurse was busy in another hospital section. The only other medical person present was junior anesthesia trainee.

EVENTS: The patient developed respiratory difficulty within about 12 minutes. His oxygen saturation fell to critical low levels. He lost responsiveness to verbal instructions. The two healthcare providers recognized the crisis and the need to intubate, but were unfamiliar where the closest emergency equipment was stored. Help was called for. After a brief cardiac arrest the patient was successfully resuscitated and intubated. Surgery was cancelled, and the patient ventilated overnight in an intensive care unit. The patient was successfully extubated the following day.

COMMENTS: The crisis was considered due to the patient developing an ipsilateral phrenic nerve block. With his medical conditions he was unable to tolerate the phrenic paralysis and developed a hypoxic cardiac arrest. Resuscitation was suboptimal due to delay in obtaining resuscitation equipment. In fact the “red cart” with all needed resuscitation equipment was outside the procedure door in the corridor. The anesthesiologist did not know that, at the time.

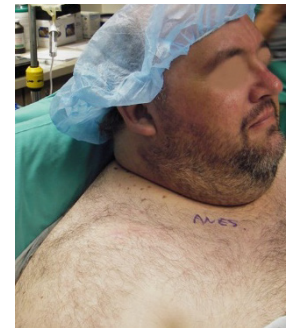Lessons learned were; (1) as far as possible never perform a major nerve block like an interscalene block without best trained assistance immediately available to help, (2) only ever perform a major nerve block like an interscalene block in a facility set up to provide ASA monitoring, and the ability to manage the airway {oxygen source, Ambu bag, laryngoscope, endotracheal tubes, laryngeal mask etc.} easily, (3) identify patients BEFORE injecting an interscalene block who likely will not tolerate the loss of one phrenic nerve becoming paralyzed. Manage those last patients in a different fashion.

Patient number 2.

The patient is 45 years old morbidly obese male needing repair of his rotator cuff. He suffers from severe obstructive sleep apnea, and is on chronic oral opiates. He appears slightly dyspneic in sitting bed and cannot lie flat.

ANESTHESIA PLAN;

1. General anesthesia and controlled intubated ventilation during the surgery. Local anesthetic gel applied to endotracheal tube tip.
2. Intra-operative opiate dependence reduction strategies; Ketamine 50mg, IV NSAIDs, zero opiates, and IV Acetaminophen.
3. *Phrenic nerve managed* regional anesthesia.
 - Interscalene catheter
 - No pre-anesthesia drugs
 - Catheter injected 1st bolus with 20ml 0.375% Ropivacaine after initiation of general anesthesia and intubation.
 - Infusion with 0.2% ropivacaine at 5 ml per hour started after successful extubation after surgery and recovery from anesthesia.
 - High level monitoring and nursing care.
 - Shoulder-targeted subcutaneous superficial cervical plexus block with 10 ml 0.5% bupivacaine prior to surgery.



OUTCOME; Surgery was 4 hours long. He recovered swiftly for general anesthesia. He was able to breath vigorously upon command and he denied having (head shake) pain or feelings of breathing difficulties. Successfully extubated and observed for 10 minutes. Transferred to operating room recovery area for 60 minutes uneventful observation. Transferred to high care area for two nights of observation. Interscalene catheter infused until morning of postoperative day number day 2. Discharged to home care late on day number two after surgery on oral non-sedating opiates.

COMMENTS: Typically with an interscalene block the phrenic nerve block is unnoticed in relatively healthy patients. The phrenic nerve block also is at the “edge” of the drug spread and it lasts less than half the duration of the analgesia. By reducing both the volume of injected drug and concentration of the injected drug from full dose and full concentration, ensured any phrenic block that could be critical would potentially resolve before the patient left the operating rooms. By



delaying the nerve block bolus until after induction of general and intubation meant the surgery could be performed without risk of cancellation or serious complications. The recovery and assessment of the patient after surgery could be done under controlled circumstances with staged safe decision making.

Patient number 3. An ASA1 healthy 17 year girl needed to have clavicle fracture surgically reduced and plated. She was administered a single shot interscalene block with 40 ml of 0.75% ropivacaine prior to surgery. General anesthesia was also used. Recovery was uneventful, completely pain free. Nerve block analgesia lasted 18 hours and subsequent pain was easily managed with oral non-sedating analgesic combinations.

Patient number 4. A healthy 25 year male had winged scapula needing surgery. The winged scapula was due to fractured ribs from football injury severing the long thoracic nerve. The surgery plan was to expose the deep surface of the scapula blade, and attach it to the exposed underlying ribs. The attachment would use plates and wires to hold the scapula down until bone uniting occurred between ribs and scapula. The surgical incision would be from posterior onto the scapula and chest.

ANESTHESIA PLAN: Interscalene block with catheter and 40 ml of local anesthetic to seek to block T1 as well. A T4 paravertebral catheter with a bolus of 15 ml to seek a T1 to T7 spread of local anesthetic.

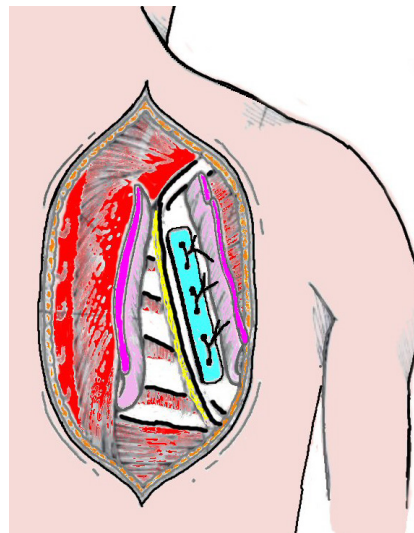
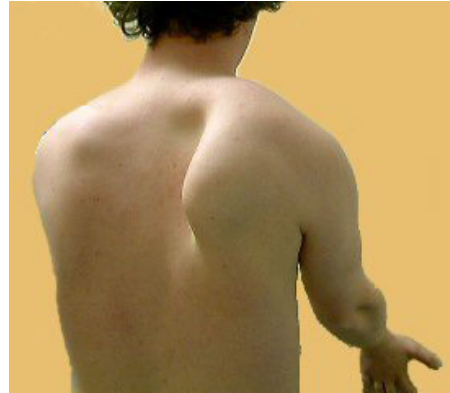OUTCOME: The patient had zero pain after surgery and through the first night after surgery. All outcomes were excellent.

COMMENT: The patient needed standard interscalene block for the scapular manipulations. The patient needed a thoracic paravertebral block for the skin incision and rib surgery. This was “dermatomal sandwich”.

Patient number 5. A 65 year old male with chronic obstructive airway disease, severe emphysema and obstructive airway disease needs shoulder arthroplasty.

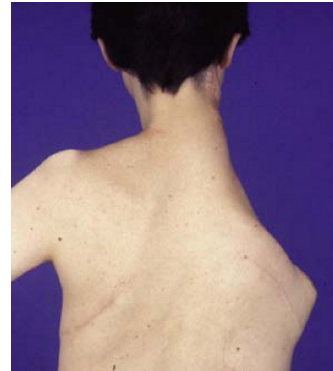ANESTHESIA PLAN: General anesthesia, tracheal intubation, and phrenic nerve sparing regional anesthesia was done. The regional anesthesia consisted of all single shot nerve blocks. The following nerve blocks were done prior to general anesthesia and surgery.

1. Ultrasound guided suprascapular block with 10 ml of 0.75% ropivacaine.
2. Subcutaneous superficial cervical plexus block in a “shoulder preferred” position, using 10 ml 0.75% bupivacaine 0.375% with adrenaline (epinephrine).
3. Ultrasound guided infraclavicular pectoral nerve block using 10 ml 0.75% ropivacaine.
4. Ultrasound guided infraclavicular axillary nerve block. This is in fact a posterior cord block and nerve stimulator evidence of finger, wrist, or elbow extension is all considered a good end point in positioning the needle tip. Ten milliliters of 0.75% ropivacaine was injected.



OUTCOME: Everything was successful and uneventful. The patient enjoyed a total pain free recovery and had substantial analgesia lasting eighteen hours. Thereafter pain was adequately managed using combination non-sedating oral analgesics drugs. Opiate rescue analgesia was kept modest used the patient was satisfied.

Patient number 6. A forty year male presented for shoulder joint arthroplasty. He had no phrenic nerve on the contralateral side due to its accidental excision during a previous cardiac surgery pericardial resection. He was reasonably functional having only one phrenic nerve, but clearly totally dependent upon it to breath. He had no other health problems of note



ANESTHESIA PLAN; Obviously an interscalene block could be done, provided the airway and ventilation were secured before injecting the block, and kept secured with ventilatory until after full recovery from the block. It was decided however to maximally avoid an interscalene block considering a risk for permanent phrenic nerve block to be 1 in 10 000. The patient was offered the four nerve phrenic-sparing combination of blocking the axillary, pectoral, supraclavicular, and suprascapular nerves nerve. The patient declined regional anesthesia. Surgery and general anesthesia was proceeded with. At conclusion of surgery a periarticular local anesthetic infiltration was done by the surgeon. After surgery the patient had severe pain, but was stoic and minimally complaining. Maximum use was made of oral non-sedating oral analgesics and opiates were used as rescue analgesia. The patient did generally well, and was discharged 3 days later. He said pain had been bad, but he was very satisfied with his total medical care and everyone's concern for him.

Patient number 7. The patient was a mature teenager needing a forequarter amputation for reasons of cancer. An interscalene block with a T4 thoracic paravertebral block was done. Both blocks were sustained with continuous infusions via catheter. The patient's recovery was excellent with absolute zero pain initially and minimal pain on all the combination analgesia once the local anesthetic infusions were stopped on the morning of day number three.

{These case reports are educational cases and not precise detailed individual clinical case reports. Some simplification has been applied for educational purposes. Every case however accurately represents this author's real experiences either as a case personally managed, or as a case that an immediate peer managed. Some photos are of the author's own patients, and some are borrowed for other public sources as representative images. This author has consent for use of all patient images that are his own patients. Many consent are written. Some consents were verbal, but evidenced in camera facing smiles amongst the series of photos.}

CONCLUSION

Regional anesthesia utilizing easy and common nerve blocks can be applied to all types of shoulder surgery. The only requirement is knowledge of the various tissue nerves supplies. For the less common surgeries it is common to need two or more nerve blocks to cover the tissues in the dermatomal sandwiches of the anterior and posterior shoulder girdle regions.

A simple interscalene block however is perfect for 95% of shoulder surgery cases.

Bibliography

- I. **Anesthesia and orthopedic surgery**. AP Boezaart. McGraw Hill. 2006
- II. **Development of the shoulder girdle**. The Vertebrate Skeleton. Sidney Hugh Reynolds, Cambridge At the University Press 1897, Reprint Kessinger Publishing's, USA.
www.kessinger.net
- III. Anesthesiologist's Manual of Surgical procedures. 4th Ed. RA Jaffe. Walter Kluwers/ Lippincott Williams & Wilkins. 2009.

Scientific References on request.

The Author;

Robert M Raw MD

MBChB, MFGP, MPraxMed, DA, FCA

2177 Port Talbot place, Coralville, Iowa 52241, USA

Career outline;

- Born in South Africa.
- Studied eight years full time before entering general medical practice.
- Seven years in rural family medicine; delivered babies, did caesarean sections, worked in the emergency room, did anesthesia, and did minor surgery.
- Studied anesthesia for 4 years.
- Worked as a specialist anesthesiologist for 14 years in private practice, in a metropolis of 7 million people. Covered all fields including neurosurgery, neonatal and pediatric surgery, vascular surgery, orthopedic surgery, and had an extensive sedation practice.
- Work 14 years in academic anesthesia at the University of Iowa.
 - Professor of Anesthesia.
- Special interest fields; (i) medico-legal expert in malpractice cases, (ii) regional anesthesia and acute pain control, (iii) lecturing and teaching anesthesiology.
 - Dr. Raw remains however a generalist at heart with a healthy interest in all aspects of anesthesiology.
- Countries lectured or presented in: South Africa (multiple), Zimbabwe, Kenya, Canada, Sri Lanka (2x), United Arab Emirates (2x), USA (multiple), England, Italy (2x), Jordan (3x), and Mexico National meetings (2x).

¹ Pohl A, et al. Cerebral ischemia during shoulder surgery in the upright position: a case series. J Clin Anesth. 2005. 17:463-469

² Kotha R, et al. Shoulder surgery in the beach chair position. Advances in Anesthesia. 2014.
<http://dx.doi.org/10.1016/j.aan.2014.08.008>

³ Sviggum HP, Hebl JR, et al. Perioperative nerve injury after total shoulder arthroplasty. RAPM 2012. 37:490-494

⁴ Boogaerts J, et al. Toxicity of bupivacaine encapsulated into liposomes and injected intravenously: comparison with plain solutions. Anaesth analg. 1993;76(3):553-5

⁵ Routman HD, et al. Local injection of liposomal bupivacaine combined with intravenous dexamethasone reduces postoperative pain and hospital stay after shoulder arthroplasty. J Shoulder Elbow Surgery 2017;26:641-647

⁶ Cao X, Pan F. Comparison of liposomal bupivacaine infiltration versus interscalene nerve block for pain control in total shoulder arthroplasty: A meta-analysis of randomized control trials. Medicine (Baltimore). 2017;96(39):e8079

⁷ Wang K, Zhang HX. Liposomal bupivacaine versus interscalene nerve block for pain control after shoulder arthroplasty: A systemic review and meta-analysis. In J Surg. 2017 Oct;46:61-7.

⁸ Yan Z, et al. Liposomal bupivacaine versus interscalene nerve block for pain control after shoulder arthroplasty: A meta-analysis. Medicine (Baltimore). 2017 July;96(27):e7226

⁹ Namdari S, et al. Randomized controlled trial of interscalene block compared with shoulder arthroplasty with injectable liposomal bupivacaine. J Bone Joint Surg Am. 2017;99:550-6

¹⁰ Abildgaard JT, et al. Liposomal bupivacaine versus indwelling interscalene nerve block for post-operative pain control in shoulder arthroplasty: a prospective randomized controlled trial. J Shoulder Elbow Surg. 2017;26:1175-1181

¹¹ Okoroha KR, et al. Liposomal bupivacaine versus interscalene nerve block after shoulder arthroplasty: a prospective randomized trial. J Shoulder Elbow Surg. 2016;25:1742-1748

DISCLAIMER: The material author(s) and Regional-Anesthesia.Com LLC, Iowa USA produce this material in best faith, from best scientific materials and in the perspective of personalized medical experiences. The material author(s) and Regional-Anesthesia.Com LLC, are not responsible for any material influencing medical practice, such is drug doses, drug indications, procedural recommendations and similar etcetera in any way that can be blamed for any patient bad medical outcome or medical misadventure. Every medical practitioner who has viewed these materials is solely responsible for their own medical practice, and the responsibility is on them to assure they have acquired best and most correct information in their preparation and studies to provide medical care.

This material **Copyright** is owned by Regional-Anesthesia.Com LLC, 2177 Port Talbot Place, IA51141, USA. It may be printed for free by one individual, for that single individual use.

If any institution, company or body wishes to print this material in numbers more than one, or any other material to be found at www.regional-anesthesia.com, or distribute it in any digital format, it must please contact the Editor of Regional-Anesthesia.Com and make a financial offer. The fee will be variable based upon country size, the size of the institution or body, and whether the institution, body or group are charging fees to the persons to receive the material. Strong consideration will be given to the proposed fee.

Regional-Anesthesia.Com LLC does have an altruistic primary goal of education and advancing patient care via regional anesthesia. **Regional-Anesthesia-Com LLC** however, has limited income sources to sustain its continuance and needs donations, advertising fees, and royalty payments.