



## The Place of the TAP block in Anesthesia. (June 2018)

Robert M Raw MD

MBChB, MFGP, MPraxMed, DA FCA

Professor of Anesthesia to 2016.

Editor of Journal of Regional-Anesthesia.com (JRAC)

### INTRODUCTION

The sensory nerve supply of the abdomen is complex and abdominal surgeries are very variable in position within the abdomen, and in size. Therefore, not all nerve blocks for the abdomen provide effective analgesia for all abdominal surgery types. Some regional analgesia interventions have serious complications (e.g. epidural hematoma), and some require special skill and training, while others are relatively safe and easy. The key to choosing the best regional analgesia technique is to (i) understand the physiology and anatomical pathways of abdominal pain, (ii) know the specific surgeries, and (iii) know the regional anesthesia technique options available.

The epidural and the spinal blocks are the standard and most widely used regional anesthesia techniques for abdominal surgery. They clearly are too invasive, too dangerous, or too short acting as single shot procedures for many of the smaller and minimally invasive abdominal surgeries. Also, there may be patient contra-indications to neuraxial blocks such as anti-coagulation therapy. Other nerve blocks are then needed that can provide post-surgical analgesia.

This lecture is focused only the TAP block. TAP blocks are best suited to surgery exclusively or dominantly confined to the abdominal wall. In the last fifteen years *ultrasound guided abdominal wall* blocks have become popular. These blocks are best suited for surgeries that have a minimal visceral peritoneal component. These blocks are finding a place in pediatric anesthesia, in ambulatory abdominal surgery in adults, and in very sick ICU patients. The benefit of these nerve blocks in the ICU is that they provide non-sedating analgesia for abdominal surgery to facilitate weaning from ventilators, but where there are contra-indications to epidural anesthesia. Ambulatory abdominal surgery is common in gynecology. A TAP block is easier and safer than a thoracic paravertebral block.

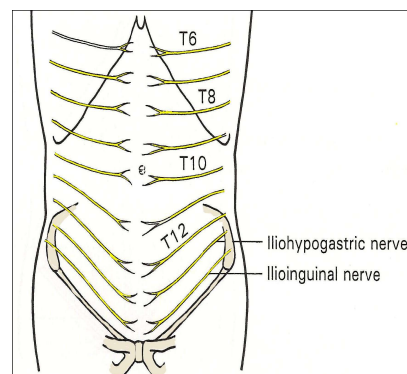
It is as also important to understand how deficient a TAP block will be when the visceral component of the surgery is large. Visceral pain can exceed somatic pain both in magnitude and in duration. For surgeries with large visceral pain components performing a TAP block would be worthless and improper.

### ❖ Nerve anatomy of the abdominal wall, and the abdomen.

The abdomen has a number of components that can be nerve blocked;

1. The abdominal wall.
2. The diaphragm.
3. The viscera and visceral peritoneum.
5. The parietal peritoneum that lines the abdominal wall.

1. **The abdominal wall** consists of skin, subcutaneous fat, muscle-fascia layers, and an inner lining of peritoneum. These tissues all share the same nerve supply, which is a segmental somatic nerve supply direct from the spinal cord



**Figure 1.** Nerves of the abdominal wall.

Attention, academic supporters, sponsors and advertisers. This banner space on page #1 of this document, is available for advertising on the web available free copies of this lecture, at [Regional-Anesthesia.Com](http://Regional-Anesthesia.Com). You can also place a dynamic link on the banner, to your website. If interested contact [editor@regional-anesthesia.com](mailto:editor@regional-anesthesia.com) for information.

as anterior ramus intercostal nerves from T6 to L1. The center dermatome of that range is at the umbilicus which has a T10 nerve supply. See figure number 1. Any block of an intercostal nerve will block the corresponding segment of abdominal wall in its full thickness from skin to peritoneum. The very lowest part of the abdomen receives its nerve supply from Lumbar root 1 via the ilioinguinal and iliohypogastric nerves.

*The genitofemoral nerve* (roots L1-2) arises from the lumbar plexus within the psoas muscle. It emerges anterior on the psoas muscle, and runs along it under the fascia iliaca. It next divides with one portion entering the medial inguinal canal and the other entering the femoral triangle passing behind the inguinal ligament and lateral to the femoral artery. See figure 1.

*The iliohypogastric nerve* (root L1) arises from the lumbar plexus within the psoas muscle, emerges on the lateral side of the psoas muscle, and runs anterior to quadratus lumborum, to pierce the transversus abdominis fascia deep to the triangle of Petit. See figure 1 and 2.

The triangle of Petit is also called the inferior lumbar triangle. The triangle of Petit lies in between the muscles latissimus dorsi (posterior), the external oblique (anterior) and the iliac crest (inferior). The Iliohypogastric nerve then runs in this transversus abdominis plane (TAP) and gives off a lateral cutaneous branch 2 cm anterior to the triangle of Petit. The remaining anterior cutaneous branch, remains in the TAP plane until it reaches 2 cm medial to of the Anterior Superior Iliac Spine (ASIS) where it penetrates the internal oblique muscle to run further to infero-anterior between the two oblique muscles before it finally become subcutaneous 3 cm cephalad of the superficial inguinal ring.

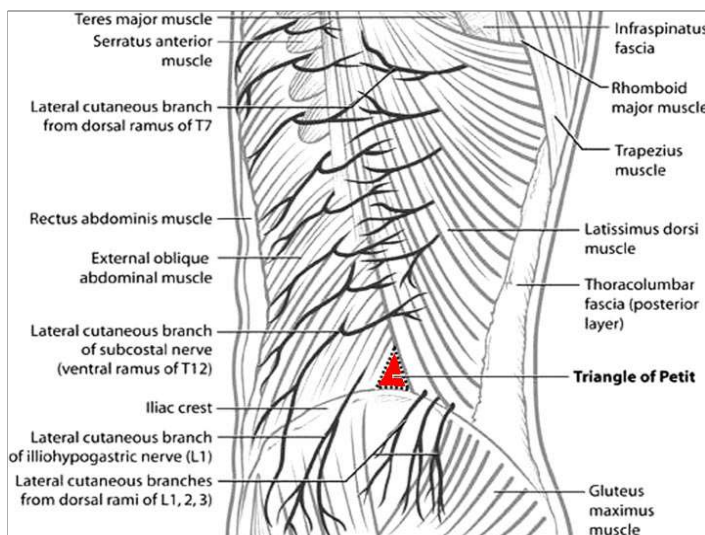


Figure 2. Abdominal wall nerve supply, viewed from lateral.

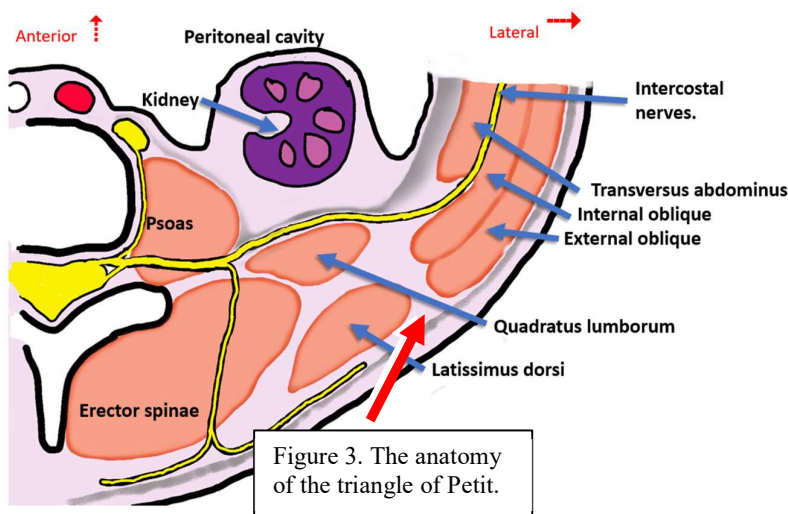


Figure 3. The anatomy of the triangle of Petit.

The transversus abdominis plane (TAP) was originally described as the fascial space *in between* the internal oblique muscle and the transversus abdominis muscle. See figures 2 and 3. The TAP plane extends from posterior immediately lateral to Quadratus lumborum muscle to near midline where the transversus fascia merges with the posterior fascia of the

rectus muscle sheath near the midline (figures 4 and 5).

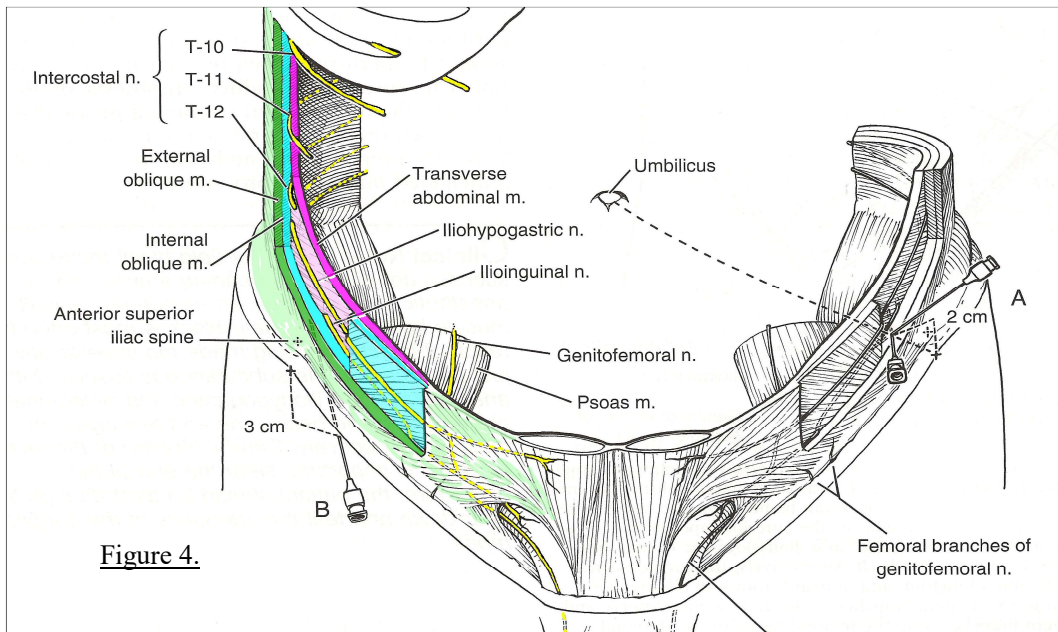


Figure 4.

Superiorly this space is limited by the abdominal wall muscle attachments to the ribs and inferiorly this TAP space is limited by the abdominal wall attachments to the iliac crest and inguinal ligament.

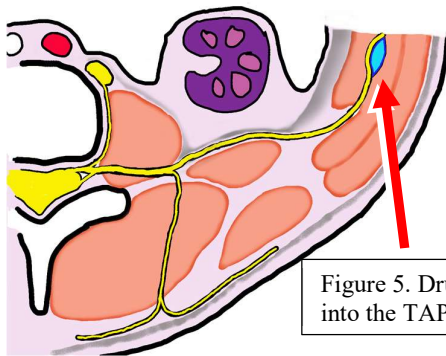


Figure 5. Drug injected into the TAP space.

The TAP space is misleadingly named. It is not truly a space between two sheets of fascia. See figure number 6. There is only one sheet of fascia between the innermost abdominis transversus muscle and the adjacent

more superficial muscle, the internal obliquus muscle. Each of these two muscles is lightly attached to this TAP fascia. All the intercostal nerves and blood vessels are loosely buried WITHIN the TAP Fascia. Both these two muscles can be stripped off the TAP fascia very easily.

One cannot create the TAP Space by open dissection of a cadaver (author's research), or by fluid injection during an ultrasound guided TAP block.

A visible sonographic space can be seen with fluid injection, to form in one of two manners. On ultrasound the TAP fascia may move deeper and the internal obliquus bulge upwards with the new fluid cavity lying between these two structures. See figure 6, image A.

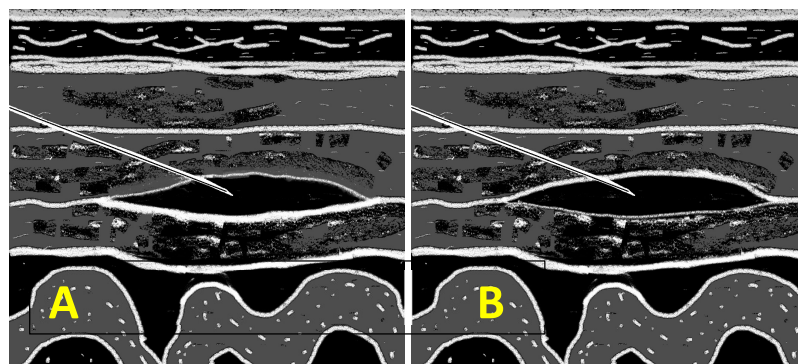


Figure no. 6. Sketch sonograms of the TAP space filled with injected local anesthetic drug. In image A the fluid is above the TAP fascia. In image B it is below the TAP fascia.





Alternatively, the fascia may move towards superficial with the transversus abdominis muscle bulging downwards and the fluid cavity is held between the two structures. See figure 6 image B. In one situation the fluid is below the fascia and in the other the fluid is above the fascia.

Clinical experience suggests that the resultant nerve blocks perform identical. This alters the concept of performing the nerve block slightly. It is now easiest and most practical is to only simply advance the needle to the point where it is felt and seen to be pushing on the TAP fascia. There is no reason to penetrate the fascia with the needle. Start injecting at that point. It will be seen that a visually well-defined fluid space forms above the fascia as the internal oblique muscle is fluid dissected off the fascia. If it appears on sonogram that there is a fascia limiting the superficial boundary of the fluid cavity it is always clearly less substantive than the actual TAP fascia that is on the deep side of the new fluid cavity. This is a very easy nerve block to perform. If one accidentally formed the fluid compartment below the TAP fascia there is no need to readjust the injection. The nerve block will function as well.

## **2. Diaphragm nerve supply.**

The peripheral diaphragm receives its nerve supply from intercostal nerves, but the central part of the diaphragm and the crura get theirs from the phrenic nerves (C3, 4, 5) centrally and about the crura. This arrangement includes the corresponding muscles, fascia, tendinous parts and peritoneal covering of the diaphragm. With esophageal hiatus surgery the crura can be sutured closer to each other. Thus, the crura may need to be nerve blocked, as well. Pain from the crura can be severe and is referred to the shoulder. The only options for that are one-sided intentional phrenic nerve block, on the side of the pain, or an intraperitoneal block.

## **3. The abdominal viscera and visceral peritoneum nerve supply.**

Pain signals are carried in both sympathetic and parasympathetic autonomic fibers.

Sympathetic fibers for the abdomen originate from spinal cord segments T5 to L2. Those fibers exit the cord as gray rami communicantes to enter the sympathetic chain in the paravertebral position. The fibers T5 to T12 pass through the coeliac plexus. They supply the viscera up to the colon at its splenic flexure. Distal to that, the distal 2/3 of the colon and the pelvic organs are supplied by the pelvic splanchnic nerves deriving from S2 to 4 spinal nerves.

Parasympathetic fibers come from two sources; (a) everything in the upper abdomen is supplied via the vagus nerve, except (b) for the colon distal to the splenic flexure and the genito-urinary organs, which receive their parasympathetic fibers from (b) the spinal cord segments S2 to 4 via the inferior hypogastric plexus.

Typical somatic pain from the abdominal wall is typically very associated with movement, can be modest during total immobility, and resolves very swiftly. In contrast, visceral pain is very severe in a sustained burning fashion, is unrelieved by position changes or resting, but is only of short duration. It typically lasts only 24 to 30 hours only. Treating only the somatic pain will barely help a patient who has severe untreated visceral pain from large visceral surgery, e.g. a colectomy. A Tap block treats only somatic pain. A local anesthetic based epidural infusion that also blocks the roots of the sympathetic nerve supply of the abdomen will substantially help with post-surgical upper abdominal pain relief, but not totally due to the unblocked parasympathetic nerve supply, via vagus, to the upper viscera.

So awake upper abdominal surgery is impossible without near anesthesia grade sedation-analgesia to cover the parasympathetic pain. Lower abdomen awake surgery, e.g. a caesarean section is fully possible under epidural anesthesia as both the



parasympathetic nerve supply and the sympathetic visceral nerve supply is blocked by epidural block for the lower abdomen.

The worth of a TAP block for abdominal surgery is in proportion to how little visceral interference occurs. For example, hernia repairs respond well to TAP blocks. Caesarean section patients have little enough pain after a TAP block for it to be well managed with supplementary non-sedating analgesia.

ORGAN	Sympathetic sensory supply	Parasympathetic sensory supply
<b>Liver and biliary system</b>	Sensory fibers travel to the coeliac plexus, then via splanchnic nerves and paravertebral sympathetic ganglia, to spinal segments fibers <b>T5 to T10</b>	With blood vessels to the coeliac plexus and then to <b>Vagus</b> .
<b>Stomach</b>	Sensory fibers travel to the coeliac plexus, then via splanchnic nerves and paravertebral sympathetic ganglia, to spinal segments fibers <b>T7 to T9</b>	With blood vessels to the coeliac plexus and then to <b>Vagus</b> .
<b>Pancreas</b>	Sensory fibers travel to the coeliac plexus, then via splanchnic nerves and paravertebral sympathetic ganglia, to spinal segments fibers <b>T6 to T10</b>	With blood vessels to the coeliac plexus and then to <b>Vagus</b> .
<b>Small bowel</b>	Sensory fibers travel to the coeliac plexus, then via splanchnic nerves and paravertebral sympathetic ganglia, to spinal segments fibers <b>T9 to L1</b>	With blood vessels to the coeliac plexus and then to <b>Vagus</b> .
<b>Caecum, ascending Colon, transverse colon</b>	Sensory fibers travel to the coeliac plexus, then via splanchnic nerves and paravertebral sympathetic ganglia, to spinal segments fibers <b>T9 to L1</b>	With blood vessels to the coeliac plexus and then to <b>Vagus</b> .
<b>Descending colon, sigmoid, rectum</b>	Sensory fibers travel with blood vessels to the inferior hypogastric plexus and then via the lumbar sympathetic ganglia to spinal segments fibers <b>T9 to T12</b> for the descending colon, and to spinal segments <b>T11 to L1</b> for the sigmoid colon and rectum.	Via the pelvic nerves to spinal segments <b>S2 to S4</b> .
<b>Kidney and ureters</b>	Sensory fibers travel to the coeliac plexus, then via the splanchnic nerves, and paravertebral sympathetic ganglia, to spinal segments fibers <b>T10 to L1</b>	<ul style="list-style-type: none"> <li>• Upper Ureter and kidneys = With blood vessels to the coeliac plexus and then to the vagus nerves.</li> <li>• Middle and lower Ureters = Via pelvic nerves to spinal segments <b>S2 to S4</b>.</li> </ul>

#### 4. The parietal peritoneum nerve supply.

This is the peritoneum lining the inner aspect of the abdominal wall and is the same as that of the abdominal wall itself.

Autonomic sensory nerve supplies (Afferent nerves).

#### ❖ Splanchnic pain.

The large extent to which the visceral component of abdominal surgery causes pain, called *splanchnic pain*, had become forgotten in modern times. The severity of visceral pain was rediscovered with modern minimal access surgery. Despite minimal access surgical pain was as severe as before. This was due to *splanchnic pain* being unchanged. The concept of minimal access surgery being pain reducing, is deceptive. The extent of splanchnic pain is as severe as with open surgery.



Splanchnic pain was discovered in early twentieth century surgery of the abdomen performed under regional anesthesia of the abdominal wall<sup>1</sup>. In the 1930s in Europe it was common to perform abdominal surgery under regional anesthesia alone and the surgeons described visceral pain and sensation and pioneered splanchnic analgesia<sup>1,2</sup>. The surgeons at first operated under bilateral paravertebral block of the abdomen only, and then systematically assessed what handling maneuvers of viscera caused what discomfort and what added nerve blocks, e.g. coeliac plexus blocks, gave pain relief.

Splanchnic pain was rediscovered in 1971 with attempted female sterilizations by fallopian tube ligation awake under local anesthetic failed due to patient pain upon tubal traction and handling<sup>3</sup>. Subsequently in 1972 Intra-Peritoneal Regional Anesthesia (IPRA) was used with lidocaine and then awake painless sterilization procedures were first described<sup>4</sup>.

Splanchnic pain is typically intense, burning in nature, more unremitting than somatic pain which finds by comparison some relief with stillness. Splanchnic pain is only severe for a short duration like 18 to 36 hours. Furthermore surgery using CO2 peritoneal insufflation is associated with greater peritoneal inflammation that open surgery causes. That inflammation is partly responsive to NSAIDs. Local anesthetics also have anti-inflammatory effects which may augment their nerve block analgesia effects.

-----

## THE ULTRASOUND GUIDED TRANSVERSUS ABDOMINIS PLANE (T.A.P.) BLOCK

The TAP block was first described in 2001 by Rafi as the “Abdominal field block” injecting into the triangle of Petit<sup>5,6</sup>. The same block was independently described again as the Transversus Abdominis Plane block (TAP block)<sup>5</sup>. The first description was a tactile “two-pops” block performed in the triangle of Petit by McDonnell in 2004. Shortly after that it was re-described as an ultrasound guided (USG) technique after which it became widely known. No single complication is yet reported. Concomitant use of multimodal analgesia (NSAIDs etc.) is recommended.

This block is best done as an ultrasound guided technique (USG). Using ultrasound guidance the transversus abdominis plane can be accessed more easily slightly anterior to the triangle of Petit and the names of Ultra-Sound Guided (USG) Ilioinguinal, USG iliohypogastric and USG TAP block are interchangeably used to refer to nearly the same

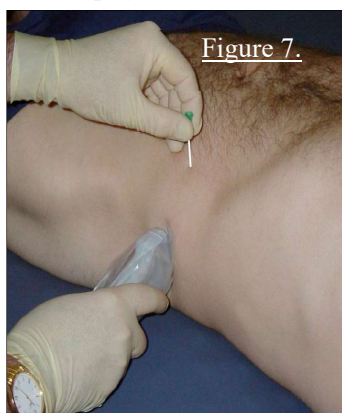

Figure 7.

block effectively for the lower abdomen. Use a Quincke point 3 ½ inch 22G spinal needle. Blunt needles penetrate fascia at shallow angles with difficulty. A sharp Quincke point is easiest to use.

One only has to be able to recognize the TAP plane in Petit’s triangle or just anterior to Petit’s triangle or just supero-anterior (subcostal) to Petit’s triangle. See figure 7. The slightly more infero-anterior position merges into the Ultra-sound guided (USG) IlioInguinal / IlioHypogastric block (II/IH block) which also uses the TAP. See figures 8 and 9.

Moving slightly anterior the muscular portions of the oblique muscle are well developed and this may assist ultrasound visualization. It is thus strongly recommended to only perform the TAP block where all three abdominal wall muscles are seen. Also, the fleshy transversus abdominis muscle gives some protection from puncturing the peritoneal cavity. It is however important not to move the injection point too anterior as fewer intercostal nerves will be blocked and also the lateral cutaneous branches of the intercostal nerves may be missed. The lateral cutaneous branches penetrate to subcutaneous in the mid axilla line.

## METHOD OF PERFORMING THE TAP BLOCK:

Place the transducer over Petit's triangle as in figure 7. That should also replicate the position of transducer "A" in figure 8. Hold the ultrasound transducer so the sound imaging plane is coronal and insert the needle *in-plane* from anterior. Insert the needle until the tip lies deep to the internal oblique muscle and superficial to the transversus abdominis muscle as in figure 17. Repeated small injections of 0.5 to 2 ml of 5% Dextrose water (5DW) can be made to precisely locate the needle tip visually.

Position "B" for the TAP block closer to the Ilio-inguinal nerve and Ilio-hypogastric nerve positions. In thin young patients, as in children the ilio-inguinal and ilio-hypogastric nerves might even be seen. Pediatric anesthesiologist might not even call this a TAP block but rather ilio-inguinal nerve block. position is well suited for inguinal herniorrhaphy as the lowest nerves receive most drug. Intercostal nerves 12 and 11 would still be reliably blocked.

Performing the block in Petit's triangle is suitable for lower abdominal surgery between the pubis and the umbilicus because intercostal roots 9 and downwards are blocked. Performing the block superior and anterior to Petit's triangle as in the "Subcostal TAP block" is better suited to upper abdominal surgery but it could NOT be relied on to include T12 and II / IH nerves.

There are two "failure" injection points.

- An injection point posterior to the triangle of Petit may find the ilioinguinal and iliohypogastric nerves have not yet entered the transversus abdominis plane. That is too close to the spinal column.
- An injection point that is too medial may miss the lateral cutaneous branches of the intercostal nerves. That is too close to the umbilicus.

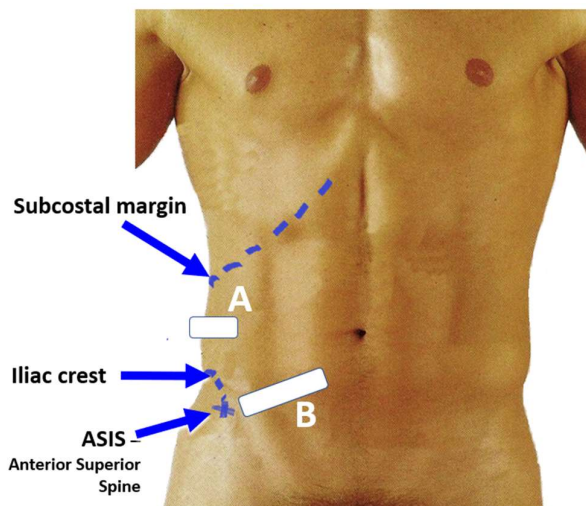
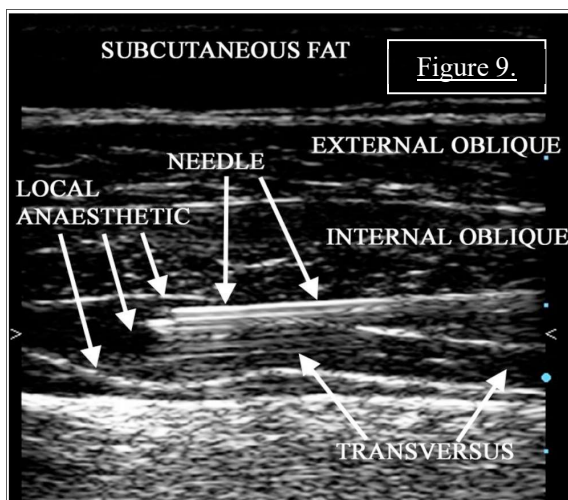


Figure 8. Two TAP block transducer positions. Position "A" is the routine one. Position "B" is better for inguinal surgery.



Have a 10 to 20 ml syringe of 5DW to inject as ultrasound image contrast and for hydro-dissection while advancing the needle. This will help place the needle confidently onto the TAP plane, before local anesthetic injection. Use a linear high frequency ultrasound transducer.

Inject 20 ml of local anesthetic in a typical adult. The fluid compartment that forms must be deep to the two oblique muscles and shallow to the transversus abdominis muscle, as seen in figure 9.

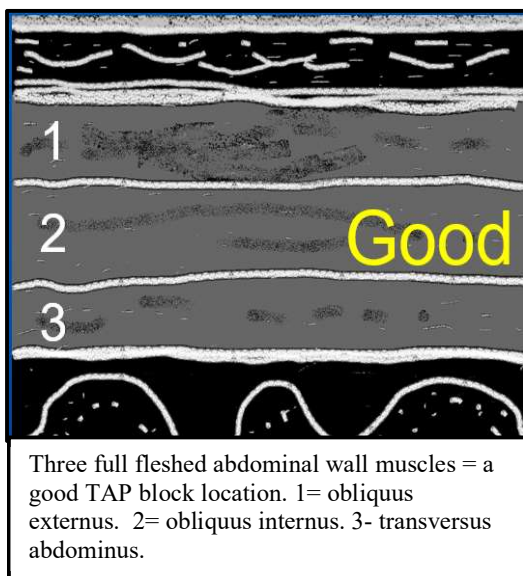
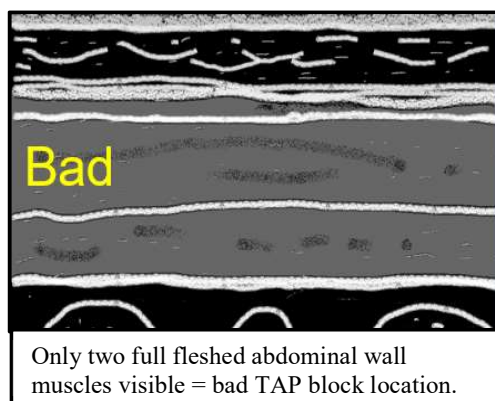
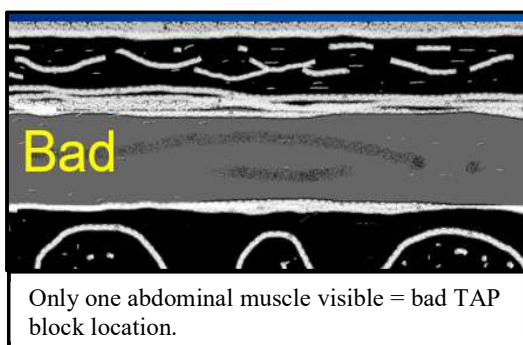




**Tips on how to optimize performing the TAP block.;**

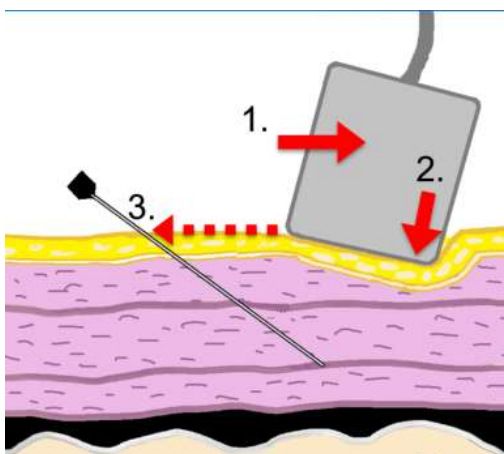
**TIP#1**

Place the transducer about fine fingers breadth cephalad to the iliac crest. Orientate the transducer in the transverse so that it lies on a line that will cross the umbilicus. Next slide the transducer sideways along that line, and find the ultrasound image that contains the three thickest abdominal muscles. The two obliques and the one transversus muscles do not all span from the front all around to the back with a fully fleshy muscle. For portions of that distance they may only exist as be tendinous fascias. Each muscle is different. There is also variation in muscularity between individuals. The point where all three muscles are fleshy is relatively lateral and is the best point at which to inject the TAP block. See the three ultrasound image sketches images below.



Sketches of ultrasound images of the abdominal wall:

There is individual variation as to where a muscle converts from a fascia layer to a muscle, then ends again as a fused fascia. The best imaging-injection spot should be as far lateral from the umbilicus as is possible to inject, but in a region with three full muscles.



## Tips on how to optimize performing the TAP block.

### Tip #2.

#### Use The retreat then heel-dig-in technique.

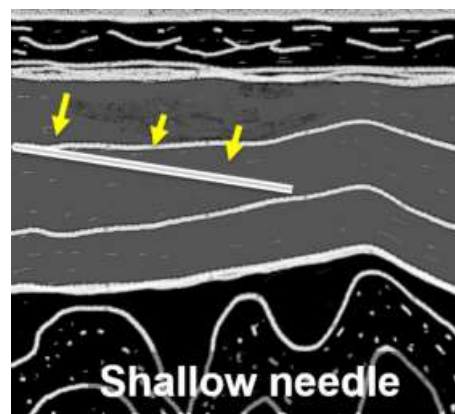
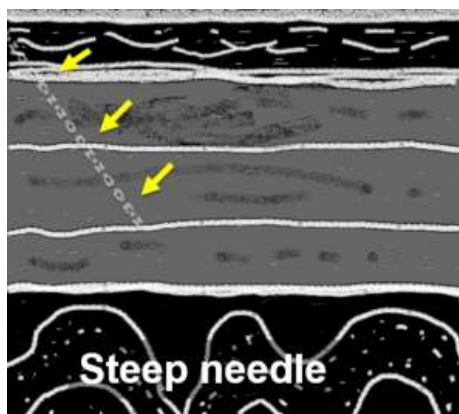
This tip can be used with all ultrasound guided nerve blocks whenever the target is deep. The best needle images are formed when the sound waves hitting the needle are perpendicular and able to all bounce back to the transducer. That occurs when the needle is parallel to the imaging surface of linear transducer.

Thus, the closer a needle can be made to becoming parallel to the transducer surface the better the needle imaging in an in-pane view.

Three handling maneuvers are needed to improve the needle and transducer being parallel.

1. RETREAT: Move the transducer sideways away from the needle insertion point. The target tissue will slide slightly out of view.
2. DIG HEEL IN: Tilt the transducer sideways so that its far lateral edge pushes (digs in) into the tissues. The target comes back into view. It is as if one took a step away then looked back to the target. This also makes the imaging surface look back to the tissue target zone that was chosen.
3. AIM SHALLOW; Insert the needle from 2 to 5 centimeters further from the edge of the transducer. This will (i) create a longer path to the target area, but (ii) aim the needle less steeply into the tissues.

These three maneuvers, in modest amounts each can improve the needle imaging dramatically. See the ultrasound images sketches below.



Two sketched sonograms. The image left shows poor needle imaging due to the steep angle of the needle relative to the transducer soundwaves. The image right shows improved, shallower, needle imaging due to the above described adjustments. Those adjustments made the sound waves hit the needle at closer to perpendicular angles.

## 2. THE ULTRASOUND GUIDED ILIOHYPOGASTRIC / ILIOINGUINAL NERVE BLOCK

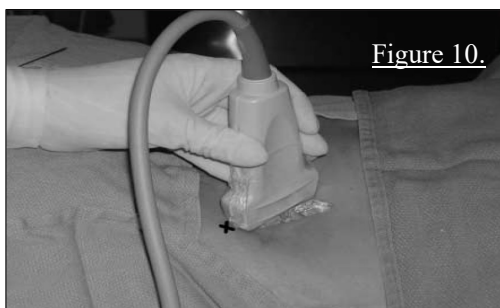

Figure 10.

Ultrasound transducer positioned at the short axis to the nerve course. X marks the needle entry point.

This block is injected immediately antero-medial to the anterior superior iliac spine (ASIS). Hold the transducer on a line from ASIS to umbilicus as in figure 8 and 10. Insert the needle from medial towards the umbilicus. Many people like an off-plane approach. Off-plane approaches are faster, once one gains confidence with that technique.

If an approach is taken from too far infero-medial of ASIS the Ilio-hypogastric nerve may have penetrated the internal oblique muscle to lie above it and under external oblique, as seen in figure 11 and 12. Theoretically drug injected in the TAP plan could then miss the ilioinguinal nerve.

Drug injected here still spreads cephalad to include the T 11 and T12 intercostal nerves. Inject 20 ml of local anesthetic in a typical adult.

This block is very similar to the TAP block near the triangle of Petit except the

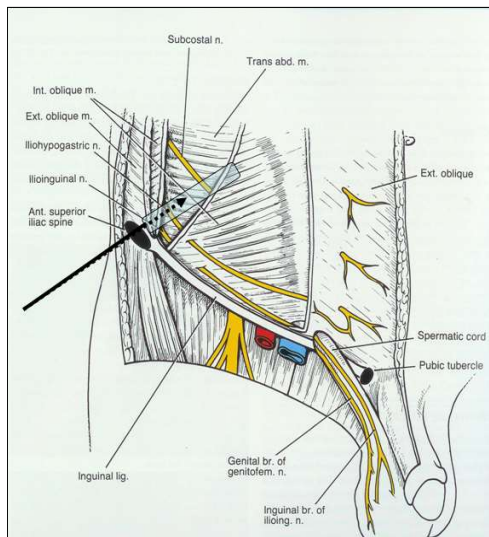


Figure 11. Ideal transducer position and needle approach for the USG Ilio-inguinal nerve block variation.

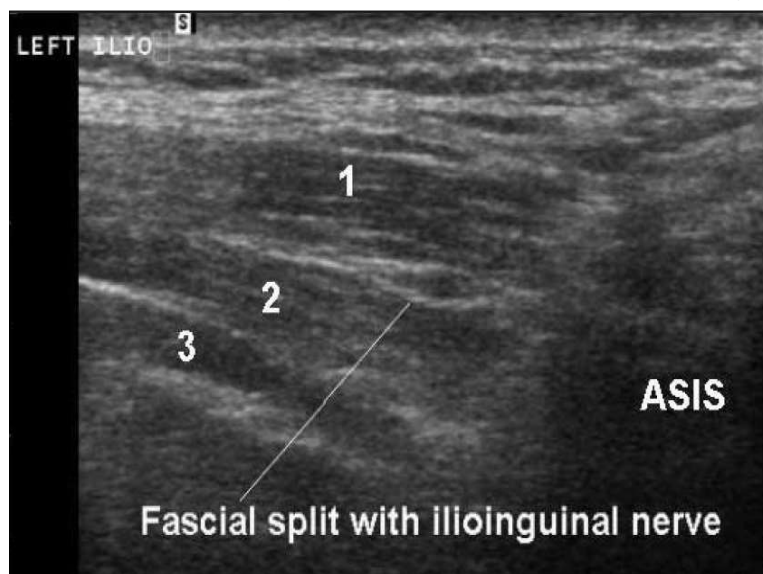


Figure 12. The ilioinguinal nerve lies above obliquus internus muscle.

For practical purposes these two nerves can be regarded as if they are blocked as one. Drug spreads to both. The ilioinguinal nerve the larger is *sometimes* seen with ultrasound, especially in children. Identifying the nerve is however not needed for block success. It is only the correct fascial plane that needs identification.

ilioinguinal and ilio-hypogastric nerves block components might last longer. The only criterion for success is to inject the drug between the transversus abdominis and internal obliquus muscles.

This ilioinguinal-ilio-hypogastric nerve block is ideal block for inguinal herniorrhaphies and abdominal wall surgery up to the T11 dermatome. For awake open surgery do an extra supplementary genitofemoral nerve block (see later).



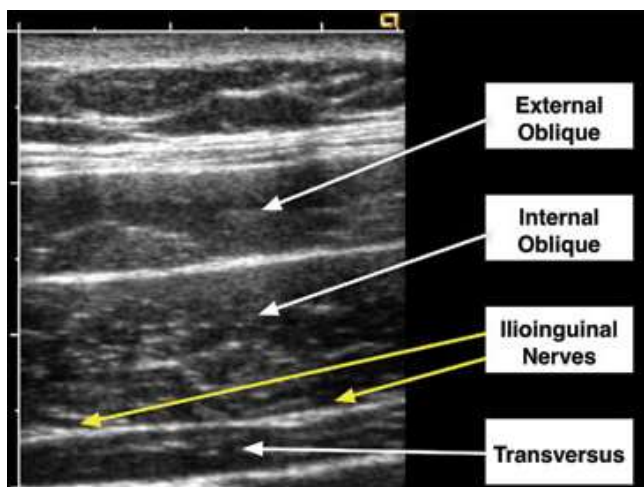


Figure 13. The transducer is correctly held in the line joining ASIS and the umbilicus, for the ultrasound guided ilio-inguinal nerve block. The ilio-inguinal nerve is visible resting superficial to the transversus abdominis muscle.

Special note; In figure 12 the ultrasound transducer was held in a plane caudad to the anterior superior iliac spine (ASIS) and the ilio-inguinal nerve has passed superficial to the internal oblique muscle to lie below the external oblique muscle.

Injection at this point could result in failure to block the iliohypogastric and 12th intercostal nerves. Examine the course of the ilioinguinal nerve in figure 11 to understand this. The best injection point is superomedial to ASIS. In figure 13 a typical ultrasound image is obtained with the ilioinguinal nerve deep to the internal oblique muscle and above abdominis transversus muscle.

### 3. SUBCOSTAL T.A.P. BLOCK

This variant is performed by injecting more cephalad than Petit's triangle and immediately anterior to the lowest ribs. It blocks the intercostal nerves of the supra-umbilical abdominal wall. A dose of 10 to 20 ml local anesthetic is recommended per side. See figure 20. Drug spreads poorly in a longitudinal axis and multiple injections, about four, are recommended. The drug volume per side can be shared between those injection points.

Position the ultrasound transducer parallel to the rib edge. The needle can be inserted in an in-plane view from medial or from lateral. A technique of *hydro-dissection* can be used to inject along the rib margin over a distance and it can be necessary to reposition the transducer as the injection progresses. Hydro-dissection uses small injections (1/2 to 1 ml) to widen the space in front of the advancing needle. The local anesthetic is used here for the hydro-dissection. This aids longitudinal spread of drug across many intercostal nerves.

NOTE: If it seems the drug is spreading poorly, lift the transducer slightly to diminish skin pressure and the drug spread within the image "slice" will improve. Drug spread is however satisfactory outside of the view field regardless.

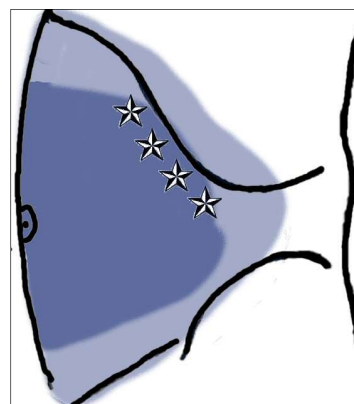


Figure 14. Subcostal TAP block. The blue color indicates the spread of abdominal wall block

### 4. THE RECTUS SHEATH BLOCK

The rectus sheath block is used for midline incisions. Typical best cases would be ventral hernia repairs and umbilical and paraumbilical hernia repairs with shorter incisions than 15 cm long. It is unsuitable for surgery involving visceral peritoneum resection. See figure number 21.



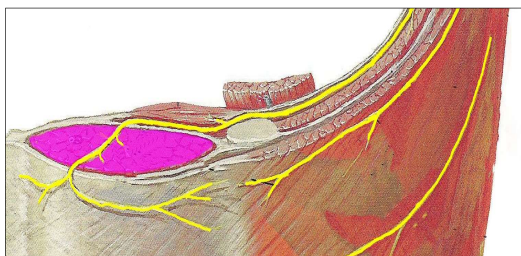


Figure 15. The rectus sheath.

This author's experience has been that if used for peri-umbilical hernia repairs with vertical incisions and the incision could be restricted to under 10 cm long 100% analgesia is usually achieved.

Inject in each of four quadrants about the planned incision. It is useful to have the surgeon mark his planned incision on the skin prior to doing the nerve block. Analgesia will extend about 2.5 cm cephalad and 2.5 caudad from each injection. The injections should be

made in the middle of the vertical plane of the rectus abdominis muscle. Each injection on one side should be 5 cm apart. For incisions 10 to 15 cm long a 6 segment (3 per side) bilateral block can be performed for larger incisions alternate blocks (e.g. subcostal TAP block) would be better.

There are two techniques for this nerve block.

- The tactile and land mark technique. Use a blunt needle like nerve block needle. By palpation confirm the side-to-side center of the muscle. Be cautious where a significant midline divarication of the muscles exists. Insert the needle perpendicular to the skin. After puncturing the skin advance the needle with tactile sensitivity. Immediately deep to the second fascial pop inject the drug. That will be immediate deep to the deep rectus muscle fascia.
- Ultrasound guided rectus sheath block. Place the transducer in the transverse orientation and insert the needle from any side in-plane. Advance the needle until it just touches the deep fascia of the rectus sheath muscle inject there. Although this is shallower than when using a tactile technique, both block techniques yield identical analgesia results.

Inject 5 to 8 ml local anesthetic per site in adults.

#### NERVE BLOCK OF THE GENITOFEMORAL NERVE FOR INGUINAL HERNIA REPAIR.

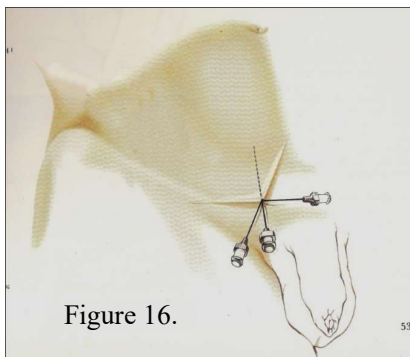


Figure 16.

This is a *supplementary* block needed if the USG Ilioinguinal-iliohypogastric block is to be used for awake open inguinal herniorrhaphy. See figure 16. The ultrasound is not used. Insert the needle direct onto the pubic tubercle. Inject 2 ml of local anesthetic then inject the balance of 10 ml total of local anesthetic drug generously in deep subcutaneous fashion aiming cephalad, then latero-cephalad, then fully lateral for about 3 cm in each direction. If the surgery is to be performed under general anesthesia one can omit this block and use multimodal analgesia afterwards.

#### ONSET OF ANALGESIA OF THE TAP BLOCK AND ASSOCIATED VARIANTS

These are all slow onset blocks compared to specific peripheral nerve blocks in limbs. Standard TAP blocks consistently block down to L1 but only to T10 by thirty minutes. It then spreads very slowly and may reach T8 or even T7 by the end of surgery. It is thus important to do this block before surgery starts in order for the analgesia to be effective upon the patient awakening.

#### SUGGESTED DRUGS AND DOSES

- Levobupivacaine 0.75% (most long acting). Analgesia lasts about 22 hours.



- Bupivacaine 0.5% to 0.25% (long acting). Preferably use preparations with added epinephrine (adrenaline). Using 0.5% bupivacaine with epinephrine (adrenaline) analgesia last about 18 – 20 hours.
- Ropivacaine 0.5% to 0.75% (medium long acting). There is no advantage to using this drug as the duration of analgesia is significantly shorter. Analgesia lasts about 8 to 10 hours

Children under 5 years old, using half-strength solutions achieve the same density of nerve block (duration) as in adults using full-strength solutions.

	USG ilio-inguinal TAP block	USG TAP block	Rectus Sheath block
Adults	<ul style="list-style-type: none"> <li>• Inguinal herniorrhaphy; 10 to 20ml per side</li> <li>• Lower abd. surgery to T10; 20ml</li> </ul>	<ul style="list-style-type: none"> <li>• 20 ml (unilateral)</li> <li>• 15 to 17.5 ml per side (bilateral) Bupiv. 0.5% + epi))</li> <li>• 20 ml per side (bilateral) (0.75% Ropiv or Levobupiv)</li> </ul>	5 – 8 ml per injection.
Children	<ul style="list-style-type: none"> <li>• Inguinal herniorrhaphy 0.25% bupiv @ 0.25ml/kg</li> <li>• Lower abd. surgery to T10 .25% bupiv @ 0.33ml/kg</li> </ul>	0.25% Bupiv @ 0.25ml/kg (per side)	0.33 ml/kg 0.25% Bupiv. shared between the 4 quadrant injections.

Infusion doses of 0.125% Bupivacaine have been used in unilateral TAP blocks successfully in adults.

### The best surgeries for TAP block analgesia.

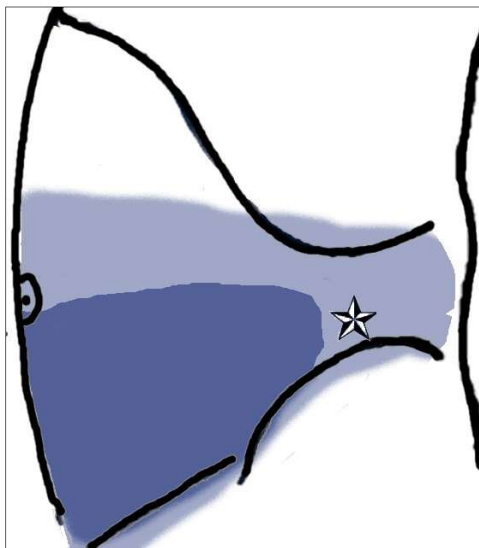
Note there must be primary anesthetic for the surgery such a general or spinal anesthetic. TAP blocks alone are rarely suitable for awake surgery. Bold text items are recommended indications.

- **Lower abdomen midline ventral hernia repair** – excellent analgesia. Single injection points are adequate.
- Upper abdomen midline ventral hernia repair – moderate analgesia. Multiple injection points are needed as the drug spreads less well when injected at the rib margins.
- **Peri-umbilical hernia repair** – excellent.
- Abdominal surgery with resection of bowels, lymph nodes, stomach or adhesions – useless.
- **Cesarean section** – moderate analgesia. The incision into the uterus is not covered by the block, but it is a small enough injury to the patient to be managed with full doses of acetaminophen and NSAIDs.
- Open Hysterectomy for a small uterus without removal of adnexa, or lymph nodes, using Pfannenstiel incision or lower abdomen midline incision. The analgesia produced is small, but it will still reduce opiate needs by 50% in the first 24 hours.
- Transvaginal hysterectomy. No benefit at all.
- **Open classic inguinal hernia repair** – excellent analgesia. Standard TAP block near the triangle of Petit works very well. A more caudad ilio-inguinal nerve block variant of the TAP block objected nearer to ASIS produces equally good analgesia, but perhaps lasting an hour or two longer. This is popular in pediatric surgery.

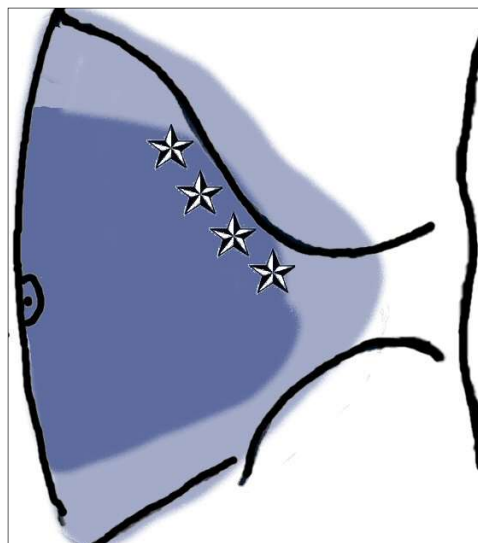
For nearly all larger abdominal surgeries, an epidural block is the optimum post-surgical analgesia technique, unless contra-indicated by e.g. anticoagulation therapy.

## SPREAD OF LOCAL ANESTHETIC WITH EACH ABDOMINAL WALL BLOCK

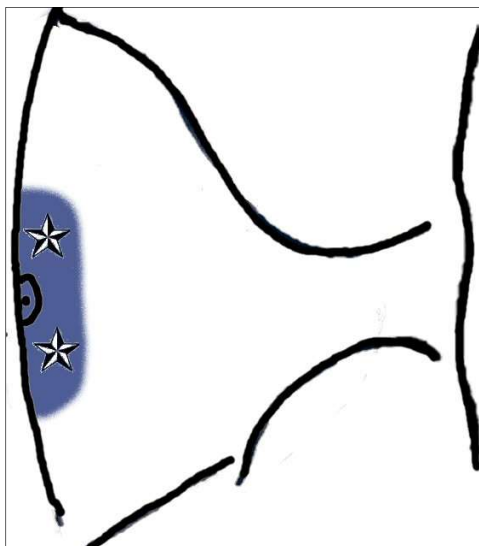
In the illustrations below, the light gray indicates the best spread of skin analgesia possible and the dark gray indicates the minimum spread of skin analgesia that can be depended upon. The stars indicate the point of injection.



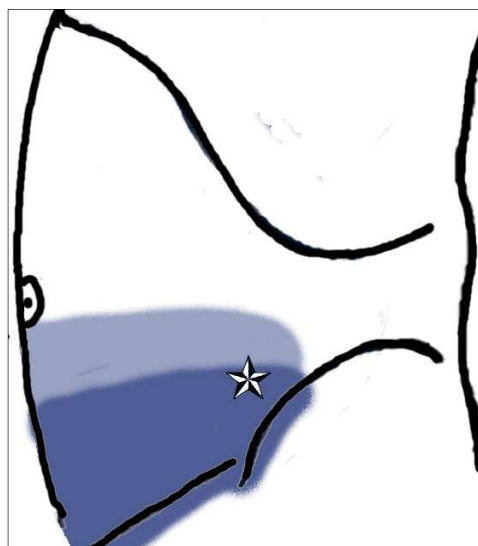
USG TAP block



Subcostal TAP block.



Rectus sheath block. Note; it is a 4-quadrant injection.



USG Ilioinguinal- Ilio-hypogastric block

## THE QUADRATUS LUMBORUM BLOCK

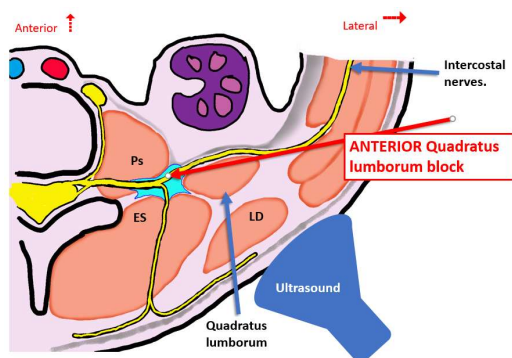
The ultrasound guided quadratus lumborum nerve block (QLB) was first described in 2007. There is some similarity to TAP blocks. In truth Rafi essentially first described the block as a tactile surface anatomy block in 2001, performed in the triangle of Petit<sup>6</sup>. Rafi called it the *abdominal field block*, and he injected after feeling the needle “pop” through two fascias. McDonnell described an ultrasound guided block in 2007 which he called the Transversus Abdominis Plane block (TAP)<sup>5</sup>. The exact sonographic views for the triangle of Petit TAP block were variable between different patients. Very soon practitioners of McDonnell’s block discovered that an improved view existed slightly more towards anterior (closer to the umbilicus) and over a point where all three abdominal wall muscles were fleshy. This produced a reliable view and that it was easy to inject the local anesthetic drugs to a point between the deepest two of the three muscles for the TAP plane. The name TAP block however was kept.

The quadratus lumborum block (QLB) is simply a return to the original Rafi’s abdominal field block, but instead using ultrasound imaging as a guide. The QLB has a different injection point to the TAP block. The quadratus lumborum muscle is used as a visual reference point. It is confusing because there are four basic QLB variants of injecting relative to the quadratus lumborum block. Each variant has many different names, and each with different needle insertion directions. Each variation behaves differently in terms of where the drug spreads to. Each variant has its own “prophet” who travels the world lecturing at conferences claiming their version is best at something. The QLB character is slightly like that of a paravertebral block although displaced slightly more lateral than thoracic paravertebral blocks by the psoas muscles. Also, there are no ribs acting as reference points. The QLB block is more challenging than TAP block which will handicap practitioners making exact precision injections each time.

Complete failure QLB has been described. Complications suggestive of neuraxial spread, and lumbosacral plexus spread have been described. That latter observation is supported by series reports of using it for analgesia for hip arthroplasty cases, although with only modest success. The overall impression is that although analgesia efficacy can be shown for all the variants, the analgesic spread is inconsistent and many individual patients experience disappointing analgesia

This author will use the classification proposed by Ueshima, for ultrasound guided quadratus lumborum blocks<sup>7</sup>. Persons reading original scientific reports must read the full article and not the abstract, to establish which *Ueshima classification* the article fits.

This author does not recommend the quadratus lumborum block over the TAP block which is uniquely easy and effective for appropriately selected surgeries.



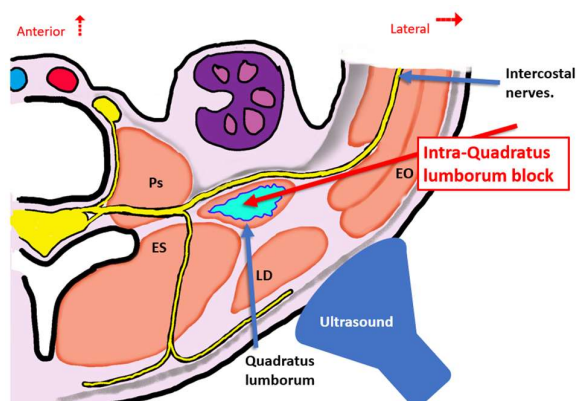
The **Anterior QLB**, labeled improperly by some as a subcostal QLB or the transmuscular QLB, is the deepest variant of the group. It is also the most difficult of the group in adults. The patient is positioned supine with a curved transducer positioned over the triangle of Petit. The needle is inserted from anterior in-plane.

The injection point is between the psoas muscle and the quadratus lumborum muscle. The drug is considered to spread on the anterior surface of quadratus lumborum muscle. That point is reached by inserting the needle through

the quadratus lumborum muscle. Because of its proximity, to the psoas muscle local anesthetic drug diffuses into the psoas muscle compartment and some features of a L2 level psoas compartment block can develop. This block is also considered a risk block to penetrate the peritoneal cavity with the needle due to its deepness and the lack of precision sonographic imaging that often occurs. In children with their enhanced ultrasound imaging compared to adults this variant has had more popularity used for acetabular-hip surgery. Efficacy is not

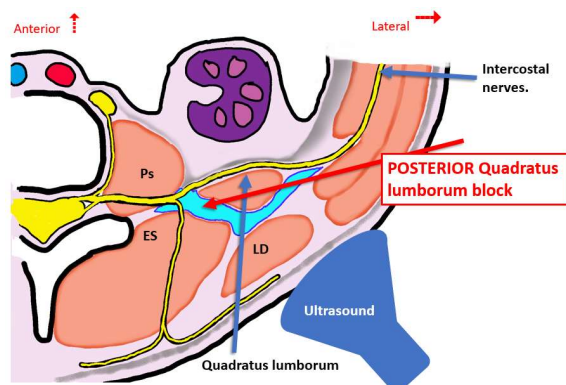


100%. This author prefers using the more specific L3 psoas compartment block supplemented with the simple subcutaneous iliac crest and subcostal nerve blocks for acetabular-hip surgery analgesia.



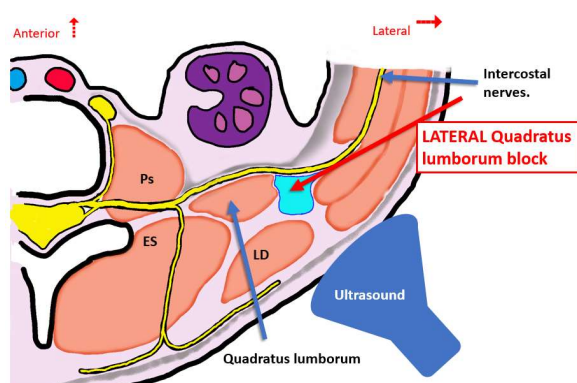
The **Intramuscular QLB** is injected into the middle of the quadratus lumborum muscle. The local anesthetic spreads up and down the muscle, and then diffuses outwards onto adjacent fascial planes and to block a range of passing intercostal nerves in the T10 to L1 range.

The patient is positioned in the supine position. The transducer is placed transverse to the patient long axis, over the triangle of Petit. The needle is inserted from anterior in-plane. Some proponents prefer a linear transducer.



The **Posterior QLB** is injected in between the erector spinae muscle and the quadratus muscle. The drug is considered to spread posterior to quadratus muscle. The drug ultimately will diffuse onto nerve structures in the region.

The patient is positioned in the supine position. The transducer is placed transverse to the patient long axis, over the triangle of Petit. The needle is inserted from anterior in-plane.



The **Lateral QLB** is injected with the patient supine and the transducer over the triangle of Petit and held transverse across the patient. The needle is inserted near the upper edge of the transducer in-plane. The tip is positioned at the lateral edge of quadratus lumborum muscle.

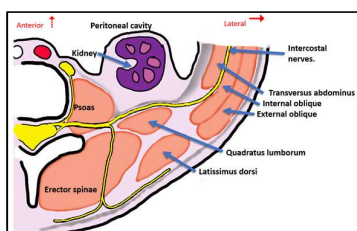
The block is considered successful, by its proponents, if sonographically the drug appears to surround the quadratus lumborum muscle.

**SUMMARISING COMMENTS;** The fact that such diverse range of QLB techniques have been shown to all cause some analgesia suggest that within the region, a large volume of injected local anesthetic almost however injected within the triangle of Petit is capable of diffusing far enough to reach some nerves in a large group of patients. It is a fact that drug that primarily bathes nerves direct will produce the fastest onset of nerve block with the longest duration in effect. For these considerations, and from experience, the author considers the TAP block superior to the quadratus lumborum group of blocks for (i) reliability of benefit for most patients, and (ii) duration of analgesia.

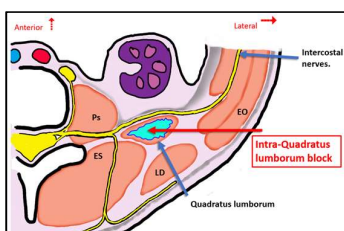


CLASSIFICATION OF THE QUADRATUS LUMBORUM BLOCK (per Ueshima)

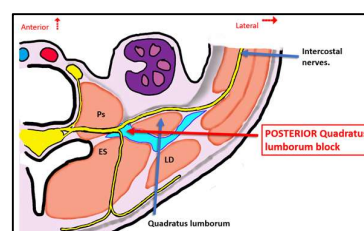
Ueshima name	Point of injection	Technical ease of block	Safety of block	Consistency of analgesia
Anterior QLB	In between psoas muscle and quadratus muscle	Difficult	Less safe	Less consistent
Lateral QLB (QLB1)	Lateral to the quadratus lumborum muscle.	Not easy	Moderately safe	
Posterior QLB (QLB2)	Posterior to quadratus lumborum muscle, in between erector spinae and quadratus muscle.	Not easy	Less safe	
Intra-QLB	Within the muscle mass of quadratus lumborum.	Very easy	Moderately safe	
TAP block	In between the transversus abdominus and interior oblique muscles	Very easy	Very safe	Very consistent



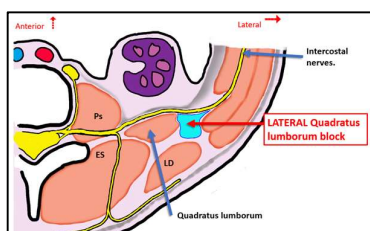
Anatomy of the quadratus lumborum block.



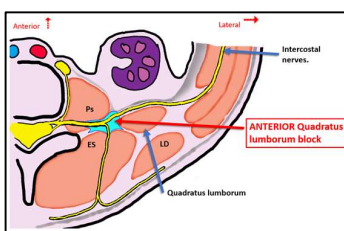
The Intramuscular Quadratus lumborum block.



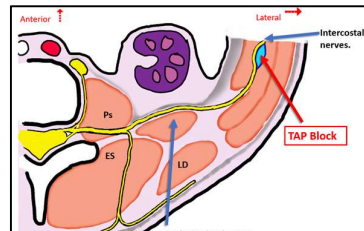
The posterior quadratus lumborum block.



The lateral quadratus lumborum block.



The anterior quadratus lumborum block.



The TAP block.



## FREQUENTLY ASKED QUESTIONS ON ULTRASOUND GUIDED ABDOMINAL WALL BLOCKS.

1. Are the ilioinguinal/hypogastric blocks (II/IH blocks) and the TAP block different blocks?  
A= **Virtually no**. They were described independently of each other each for a different patient groups. The TAP block was described for adult lower abdominal surgery. The II/IH blocks were described for pediatric inguinal surgery. When it became realized that both are best performed with USG and that approaches could be more anatomically flexible, it was realized that both block II/IH and TAP block are very similar and block the same nerves.
2. When should I do a TAP block and II/IH block?  
A = The II/IH block is best performed for inguinal hernia surgery and as a bilateral procedure for lower abdominal surgery with transverse incisions (e.g. retropubic surgery, and Caesarean sections using the transverse Pfannenstiel incision.).  
The TAP block can be used for all the IH/IH indications but is definitely superior in gaining extra intercostal dermatomes for lower abdominal surgery with incision sup to the umbilicus. With few exceptions another primary anesthetic is still needed (GA or neuraxial block), and these abdominal wall blocks are *analgesia blocks* for post-surgical pain.
3. Do the intercostal nerves of the abdomen supply the peritoneum?  
A = YES they supply the parietal peritoneum of the abdominal wall but not the visceral peritoneum of the abdominal contents which have an autonomic sensory supply.
4. Are these block useful in obese patients.  
A = If the BMW exceeds 40 these blocks are near impossible due to tissue thickness and difficulty acquiring images. With a BMI of 35 or less they are reasonably easy to do
5. Is the USG II/IH or TAP block useable for AWAKE inguinal herniorrhaphy?  
A = NO, not on its own. There are two possible areas of analgesia deficit. One relates to a repair incision impinging on the midline (Typically on the larger hernia on more obese patients). This requires a supplementary subcutaneous infiltration of local anesthetic from pubis upwards for 2 to 4 cm. Second the USG TAP/II/IH block does not include the genito femoral nerve which needs to be blocked separately. It is best blocked by injecting local anesthetic from the pubic tubercle in a supero medial direction from bone and then onwards deep subcutaneous for 2 to 4 cm.

## CONCLUSION.

The nerve supply to all of the abdomen and its content is complex, and there are very many nerve blocks that can be used in combinations that will provide optimal analgesia of abdominal surgeries. The TAP block is characterized by its ease of performance, great safety, simplicity, and high level of efficacy when used for the appropriate surgeries. The TAP block is thus a highly recommended nerve block. The user must just understand the surgeries for which it works best.

---

<sup>1</sup> Adson AW (1935) Splanchnic pain. Mayo clinic Proceedings; 10:623

<sup>2</sup> Baruch M (1921) Ueber eine directe anaesthesie de bauchhohle. Zentrabl f Chir 48:821

<sup>3</sup> Munson AK. Postpartum tubal ligation under (skin) local anesthesia. Obstet Gynecol 1972 39:756-758

<sup>4</sup> Cruikshank DP. Intraperitoneal lidocaine anesthesia for postpartum tubal ligation.

<sup>5</sup> McDonnell J. The analgesic efficacy of transversus abdominis plane block after abdominal surgery: a prospective randomized controlled trial. Anaesthes Analg 2007;104:193-7

<sup>6</sup> Rafi AN. Abdominal field block: a new approach via the lumbar triangle. Anaesthesia Oct 2001;56(10):1024-1026

<sup>7</sup> Ueshima H, et al. Ultrasound guided quadratus lumborum blocks: an updated review of anatomy and techniques. Hindawi Biomed Research International. 2017; article ID 2752876